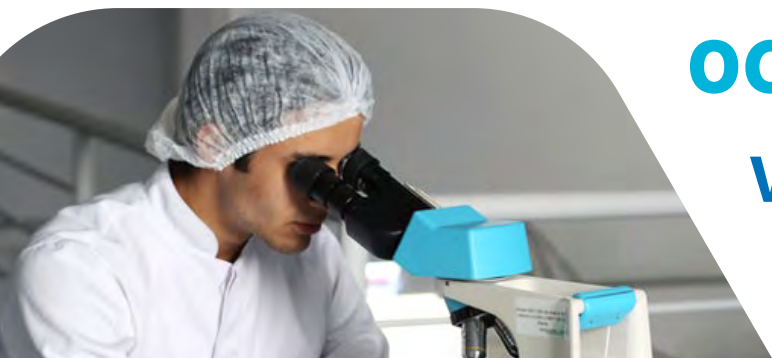




PROCEEDINGS OF 73rd ANNUAL SCIENTIFIC SESSIONS 2021

"Responsibilities and emerging
challenges of veterinarians"



**22nd & 23rd
OCTOBER 2021**
Virtual Sessions

Live from
Oak Ray Regency Hotel - Kandy



SRI LANKA VETERINARY ASSOCIATION

"Working for the advancement of the veterinary profession since 1940"



73rd Annual Scientific Sessions 2021

Sri Lanka Veterinary Association

Programme and Abstracts of the
Annual Scientific Sessions 2021

22nd and 23rd October 2021
Virtual Sessions
Oak Ray Regency Hotel, Kandy
Sri Lanka

ANNUAL SCIENTIFIC SESSIONS 2021

SRI LANKA VETERINARY ASSOCIATION

Programme

Day 1– 22nd October 2021

08.00 – 08.50	Registration and Refreshments
08.50 – 09.00	Arrival of the Guests and Ceremonial Procession
09.00 – 09.10	National Anthem and Lighting of the Oil Lamp
09.10 – 09.20	Welcome Address by Dr. P. E. Gunawardena, President, SLVA
09.20 – 09.35	Address by Mr. K. M. Roepke Regional Director-South Asia & Sub-Saharan Africa, U.S. Soybean Export Council (USSEC)
09.35 – 09.40	Address by the Guest of Honor – Dr. K. A. C. H. A. Kothalawala Director General, Department of Animal Production and Health
09.40 – 09.50	Address by the Chief Guest - Dr. N. Samaranayake Additional Secretary, State Ministry of Livestock, Farm Promotion, Dairy and Egg Related Industries
09.50 – 09.55	Vote of Thanks by Dr. G. S. Pemachandra, Secretary, SLVA
09.55 – 10.15	T E A
10.15 – 10.20	Opening Remarks by Prof. N. Alles, Co-chair, 73 rd SLVA Scientific Sessions 2021
10.20 – 11.00	Keynote Speech by Dr. A. Ambagala “Transboundary Animal Diseases and Role of Veterinarians” Head of the Mammalian Diseases Unit and the OIE Reference Laboratory for Classical Swine Fever at the National Center for Foreign Animal Disease (NCFAD), Winnipeg, MB, Canada
11.00 – 11.20	Animal Health Session-Plenary Speech by Prof. A. Dangolla “Procedures adopted by Public Health Veterinary Service of the Ministry of Health in Control & Eradication of Rabies in Sri Lanka” Professor in Veterinary Clinical Sciences, Department of Veterinary Clinical Sciences, Faculty of Veterinary Medicine and Animal Sciences, University of Peradeniya

73rd Annual Scientific Sessions of Sri Lanka Veterinary Association**11.20 – 12.35** Technical Session I – Animal Health Session

12.35 – 13.20 LUNCH BREAK

13.20 – 14.40 Technical Sessions II – Poster Presentations

14.40 – 15.05 Public Health Session-Plenary Speech by Prof. S. Kariyawasam

“Combating Antimicrobial Resistance: Responsibilities of the Food Animal Veterinarian”

Professor of Microbiology, Chair, Department of Comparative, Diagnostic and Population Medicine, Collage of Veterinary Medicine, University of Florida, USA

15.05 – 17.20 Technical Session III – Public Health Session

Programme

Day 2– 23rd October 2021

09.00 – 09.25	Clinical Session- Plenary Speech by Dr. N. Horadagoda “Diagnostic approach to lumps and bumps in small animal clinical practice; A Pathologist perspective “ Veterinary Pathologist, Veterinary Teaching Hospital, Camden, University of Sydney, Australia
09.25 – 09.50	Animal Production Session-Plenary Speech by Prof. M. D. Wheeler “Implementing the Appropriate Reproductive Biotechnologies- The Fast Lane towards Self-Sufficiency in Dairy Products” Professor of Biotechnology and Developmental Biology Department of Animal Sciences, Department of Bioengineering, Department of Veterinary Clinical Medicine, Carl R. Woese Institute for Genomic Biology (Regenerative Biology and Tissue Engineering), Beckman Institute for Advanced Science and Technology Carle-Illinois College of Medicine, Urbana, Illinois, USA
09.50 – 10.15	Wildlife and Aquaculture Session - Plenary Speech by Dr. T. Prasad “Role and Challengers of a Wildlife Veterinarian” Director-Wildlife Health, Department of Wildlife Conservation and Forestry, Sri Lanka
10.15 – 10.30	TEA BREAK
Parallel Sessions	
10.30 – 12.30	Technical Session IV – Clinical
10.30 – 12.30	Technical Session V – Animal Production
12.30 – 13.15	LUNCH BREAK
13.15 – 17.45	Technical Session IV – Clinical
13.15 – 16.15	Technical Session VI – Wildlife and Aquaculture
17.45 – 18.00	Closing remarks by Dr. D. A. Satharasinghe Co-Chair ,73 rd SLVA Scientific Sessions 2021

73rd Executive committee of the SLVA

President	Dr. P. E. Gunawardena
President Elect	Dr. M. A. S. Mallawa Arachchi
Vice Presidents	Dr. A. M. J. S. Amarakoon Dr. D. A. Satharasinghe
Secretary	Dr. G. S. Pemachandra
Asst. Secretaries	Dr. W. A. D. C. H. Wickramasinghe Dr. W. M. W. S. Wasala
Treasurer	Dr. W. A. D. N. Wickramasinghe
Asst. Treasurer	Dr. M. D. N. Premalal
Executive Members	Prof. C. N. R. A. Alles Dr. J. Y. C. Dharmasuriya Dr. H. C. Kannangara Dr. R. A. J. U. Marapana Dr. S. T. Thoradeniya Dr. K. S. Wanigasundara
Ex-Officio members	Dr. D. D. N. de Silva (Past President) Dr. K. G. J. S. Disnaka (Past Secretary) Dr. A. W. Kalupahana (Past Treasurer)

Annual Scientific Sessions – 2021

Scientific Committee

Prof. C. N. R. A. Alles (Co-Chair)

Dr. D. A. Satharasinghe (Co-Chair)

Coordinator

Dr. J. M. K. J. K. Premarathne

Track Chairs

Animal Health – Dr. K. G. J. S. Disnaka

Animal Production – Dr. R. A. C. Rabel

Clinical – Dr. H. M. S. Wijekoon

Public Health – Dr. H.C. Kannagara

Wildlife and Aquaculture – Dr. W. A. D. C. H. Wickramasinghe

Secretary

Dr. J. Y. C. Dharmasuriya

Members

Dr. D. D. N. de Silva

Dr. S.S.S.de. S. Jagoda

Dr. P. E. Gunawardena

Dr. A. W. Kalupahana

Dr. L. G. S. Lokugalappatti

Dr. M. A. S. Mallawa Arachchi

Dr. G. S. Pemachandra

Reviewers of Abstracts

Prof. P. Abeynayake	Dr. K. G. J. S. Disnaka	Dr. L. G. S. Lokugalappatti
Prof. P. A. B. D. Alexander	Dr. M. A. M. Fazi	Dr. M. A. S. Mallawa Arachchi
Prof. H. B. S. Ariyaratne	Dr. P. S. Fernando	Dr. N. Obeysekara
Prof. A. Dangolla	Dr. M. N. M. Fouzi	Dr. M. W. C. D. Palliyaguru
Prof. S. P. Gunarathne	Dr. S. Gamlath	Dr. E. Pathirana
Prof. M. P. S. Magamage	Dr. M. L. A. N. R. D. Gunarathne	Dr. S. Pemachandra
Prof. I. N. Pathirana	Dr. T. A. Gunawardhane	Dr. G. S. Perera
Prof. D. V. P. Prasada	Dr. M. H. Hathurusinghe	Dr. G. D. R. K. Perera
Prof. P. G. A. Pushpakumara	Dr. T. Herath	Dr. J. M. K. J. K. Premarathne
Prof. R. P. V. J. Rajapakshe	Dr. N. Horadagoda	Dr. N. Priyankarage
Prof. D. Ruwandeepika	Dr. M. Ijaz	Dr. M. A. R. Priyantha
Prof. I. D. Silva	Dr. S. S. S. de S. Jagoda	Dr. R. A. C. Rabel
Prof. S. Tennakoon	Dr. N. K. Jayasekara	Dr. E. Rajapaksha
Prof. K. A. N. Wijayawardhane	Dr. L. J. P. A. P. Jayasooriya	Dr. D. A. Satharasinghe
Dr. B. M. A. O. Perera	Dr. K. L. T. D. Jayawardhane	Dr. S. A. Weerasooriya
Dr. W. W. Abeygunawardhane	Dr. M. D. N. Jayaweera	Dr. B. C. Wickramasooriya
Dr. N. M. T. Anupama	Dr. R. N. Jinadasa	Dr. C. G. Wijesinghe
Dr. H. Ariyaratne	Dr. H. C. Kannangara	Dr. I. Wickramasinghe
Dr. A. Arulkanthan	Dr. A. Karawita	Dr. R. R. M. K. K. Wijesundara
Dr. D. D. N. de Silva	Dr. D. T. Kasagala	Dr. S. S. P. Silva
Dr. L. N. A. de Silva	Dr. M. A. S. D. Karunarathna	Dr. D. M. S. M. Siriwardhane
Dr. P. de Silva	Dr. K. A. C. H. A. Kothalawala	Dr. H. M. S. Wijekoon
Dr. D. R. A. Dissanayake	Dr. S. N. Kumara	Dr. W. M. P. B. Weerasinghe
Dr. R. B. Dissanayake	Dr. W. R. B. Kumara	Mr. B. A. Y. B. Jayawardhana

73rd Annual Scientific Sessions of the Sri Lanka Veterinary Association

Keynote and plenary speeches		
Time	Title and Authors	Page No
Day 1- 22 nd Oct 2021		
10.20 – 11.00	Keynote address Transboundary Animal Diseases and Role of Veterinarians <i>Dr. A. Ambagala</i>	XXI
11.00 – 11.25	Plenary Speech- Animal Health Session Procedures adopted by Public Health Veterinary Service of the Ministry of Health in control & Eradication of Rabies in Sri Lanka <i>Prof. A. Dangolla</i>	XXII
14.40 – 15.05	Plenary Speech-Public Health Session Combating Antimicrobial Resistance: Responsibilities of the Food Animal Veterinarian <i>Prof. S. Kariyawasam</i>	XXIII
Day 02- 23 rd Oct 2021		
09.00 – 09.25	Plenary Speech- Clinical Session Diagnostic approach to lumps and bumps in small animal clinical practice: A Pathologist perspective <i>Dr. N. Horadagoda,</i>	XXIV
09.25 – 09.50	Plenary Speech- Animal Production Session Implementing the Appropriate Reproductive Biotechnologies-The Fast Lane towards Self-Sufficiency in Dairy Products <i>Prof. M. B. Wheeler</i>	XXV
09.50 – 10.15	Plenary Speech- Wildlife and Aquaculture session Role and Challenges of a Wildlife Veterinarian <i>Dr. Tharaka Prasad</i>	XXVI

Day 01- 22 nd of October 2021		
Technical Session I – Animal Health (11.20 – 12.35)		
Session Chair – Dr. K.G.J.S. Disnaka		Page No
11.20 – 11.35	Pentosan Polysulfate Regulates Hecpudin 1-Facilitated Formation and Function of Osteoclasts Derived from Canine Bone Marrow <i>S. Wijekoon*, T. Sunaga, Y. Wang, C. Mwale, S. Kim and M. Okumura</i>	01
11.35 – 11.50	Measurement of Serum 5 α -pregnane-3,20-dione (5 α -DHP) and Progesterone in Female Asian elephants (<i>Elephas maximus</i>) <i>T. De Silva, I. Pathirana*, B. Bandara, L. Fonseka, H.P.R.N.S. Karunarathna, K.K. Sumanasekara and N. Kawate</i>	02
11.50 – 12.05	Occurrence and Antimicrobial Resistance of Multi-Drug Resistant Extra-Intestinal Pathogenic <i>Escherichia coli</i> ST131 clone in companion animals in Sri Lanka <i>W.A.P.M. Dewasmika* and D.R.A. Dissanayake</i>	03
12.05 – 12.20	Microbiological quality assessment of broiler feed along the feed distribution chain <i>H.C. Gallage, L.A.D.E. Weerasinghe, S. Samita, R.S. Kalupahana, H.M.T.K. Karunarathna and K.S.A. Kottawatta*</i>	04
12.20 – 12.35	Identification of serotypes involved in fowl adeno virus (FAdV) infections in Sri Lanka during 2018 - 2020 <i>N. de Silva*, M. Paniago, I. Kiss, K. Wijesundera and A. Palkumbura</i>	05
12.35 – 13.20	LUNCH BREAK	

Day01-22 nd Oct 2021		
Technical Session II -Poster Presentations – (13.20 – 14.37)		
Session Chair - Dr. W.A.D.C.H. Wickramasinghe		Page No
13.20 – 13.27	Use of MIGLIS for the Separation of Sperm with High Motility in Chicken (<i>Gallus gallus domesticus</i>) <i>C. Priyadarshana*</i> , <i>A. Tajima</i> and <i>A. Asano</i>	06
13.27 – 13.34	Management of an Unusual Case of Partial Uterine Prolapse in a Rhodesian Ridgeback <i>R.M.S. Nuwanshika*</i> , <i>K.A.R.K. Perera</i> , <i>H.M.S. Wijekoon</i> and <i>D.D.N. de Silva</i>	07
13.34 – 13.41	Morphological identification of fungi isolated from poultry feed in the North-Western Province of Sri Lanka. <i>D.P. H. Wijesekera*</i> , <i>W.D.M. Perera</i> , <i>G.D.R.K Perera</i> , <i>S.S.S. de S. Jagoda</i> <i>A.W. Kaluphana</i>	08
13.41 – 13.48	Determinants of Waste Disposal Mechanisms at Household level in Colombo Municipal Council (CMC) area <i>E.M.U. Dissanayake*</i> and <i>R.C. Gamage</i>	09
13.48 – 13.55	A Case Report on Paralytic Ileus in a Dog Presented to Veterinary Teaching Hospital <i>S.A.C.H. Rodrigo</i> , <i>S.U.G. Amarasena</i> , <i>T.M.S.K. Piyadasa</i> , <i>D.R.A. Dissanayaka</i> and <i>D.D.N. De Silva</i>	10
13.55 – 14.02	Application of risk analysis for the control of Megalocytivirus in ornamental fish in Sri Lanka <i>P. Sembapperuma*</i> and <i>A. Ponnusamy</i>	11
14.02 – 14.09	Effects of Climatic Variations on Semen Volume and Concentration of Cattle and Buffaloes in Sri Lanka; a Retrospective Study. <i>C. M. Keerthirathne*</i> and <i>U.G.V.S.S. Kumara</i>	12
14.09 – 14.16	Total Aflatoxin Occurrence in Suspected Animal Feed Samples <i>S.S.K. Daluwatta*</i> , <i>H.M.A.K.H.K. Navarathna</i> , <i>R.A.T. Chandima</i> , <i>D.M.D.P. Dissanayaka</i> , <i>D.L. Ranathunga</i> , <i>R.A.I.M. Ranasingha</i> , <i>K.W.G.S.M. Kularathna</i> and <i>M.W.C.D. Palliyeguru</i>	13
14.16 – 14.23	Dairy Cattle Importation Project of Sri Lanka: Eight Recommendations to Avoid Falling into the Same Hole Again <i>R.A.C. Rabel*</i> , <i>S.P. Gunarathne</i> , <i>M. Hanifa</i> , <i>K.S.U. Jayathissa</i> , <i>R. Mahendra</i> , <i>B.P.A. Jayaweera</i> , <i>W.A.D.V. Weerathilake</i> , and <i>D.M.S. Munasinghe</i>	14
14.23 – 14.30	Provincial Level Power Delegation in Dairy Production and Animal Health; Strength or Failure? <i>K.K.N. Laknath*</i>	15

14.30 – 14.37	Molecular Characterisation of Bacterial Isolates from Dairy Cows with Mastitis for Alternative Control Strategies <i>G. A. Gunawardana*, P.P. Jayasekara, G.A.D. Chandana, W.M.R.R. Wijethunga, M.W.C.D. Palliyeguru and R. Wimalagunaratne</i>	16
---------------	--	----

Day 01 -22 nd Oct 2021		
Technical Session III - Public Health Session (14.45 – 17.20)		
Session Chair – Dr. M. Ijas		Page No
15.05 – 15.20	A Survey of Veterinarians' Attitudes and Perception toward Euthanasia of Companion Animals in Sri Lanka <i>S.A.C.H. Rodrigo K.L.D.B.P. Liyanage, T.D.Nuwarapaksha, T. Paramanathan and D.D.N. De Silva *</i>	17
15.20 – 15.35	Non communicable disease status in zoo workers in Pinnawela with emphasis on elephant keepers <i>W.K.S.M. Weththewa, M.E.M. Liyanage, L.D.R.M. Bandaranayake, L.P. Malinga and A. Dangolla</i>	18
15.35 – 15.50	The potency of animal anti-rabies vaccines marketed in Sri Lanka <i>H. Rathnadiwakara*, A. Servat, F. Cliquet, M. Wasniewski, J.C. Thibault and M. Gunatilake</i>	19
15.50 – 16.05	Improving the Waste Management System of Medium Scale Dairy Operation to Control Odour Issue in Peri-urban Area: A Case Study <i>C.M. Namarathna *, S. Priyantha and R.M.K.P. Rajanayake</i>	20
16.05 – 16.20	Antimicrobial resistance profiles in <i>Escherichia coli</i> isolated from an urban ecosystem in Sri Lanka: A one health approach <i>Y. Gunasekara, T. Nisansala, I. Wijewickrama, Y. Basnayake, S. Kottawatta, A. Silva-Fletcher and R. Kalupahana *</i>	21
16.20 – 16.35	A Review of Laws Related to Animals and Veterinary Profession in Sri Lanka <i>H.C. Kannangara*</i>	22
16.35 – 16.50	Investigation of Antimicrobial Resistance in <i>Escherichia coli</i> Isolated from Wild Animals at Hambegamuwa: Sri Lanka <i>B.M.Y.I. Basnayake, G.G.T. Nisansala, P.I.J.B. Wijewickrama, U.S. Weerathunga, N.K. Jayasekera, A.W. Kalupahana, R.S. Kalupahana, A. Silva- Fletcher and K.S.A. Kottawatta *</i>	23
16.50 -17.05	<i>mecA</i> gene based characterization and antimicrobial resistance of <i>Staphylococcus spp</i> recovered from commercial eggs collected from layer farms in Kurunegala District <i>H.C. Gallage, H.M.T.K. Karunarathna, W.A.S.M. Premaratne R.S. Kalupahana and K.S.A. Kottawatta *</i>	24

17.05 – 17.20	Importation of antimicrobials intended for veterinary use and related regulatory measures in Sri Lanka during 2016-2020 <i>U. Sinhalagoda, M.D.N.Jayaweera*, C. G. Wijesinghe, S. Seneviratne and J. Priyangika</i>	25
---------------	--	----

Day 02 - 23 rd October 2021- Parallel Sessions		
Technical Session IV – Clinical Session (09.00 – 14.15)		
Session Chair – Dr D.M.S.M Siriwardana		Page No
10.30 – 10.45	Cutaneous plasmacytoma on a foot pad of a dog: A case report <i>I.N. Kumaravithana*, H.M.S Wijekoon and H. Ariyaratna</i>	26
10.45 – 11.00	Clinico-Pathological Diversity of Canine Oral Cavity Tumors: A Retrospective Study. <i>S.A.C.H. Rodrigo, P.G.A.S. Palkumbura, W. Jayaweera, G. S. P. de S. Gunawardena and R.R.M.K.K. Wijesundera*</i>	27
11.00 – 11.15	An aberrant movement of a gunshot pellet in a dog: A case report. <i>P.G.A.S. Palkumbura, S.A.C.H. Rodrigo, R.M.T.M. Ramanayake, G.S.P. de S. Gunawardena and R.R.M.K.K. Wijesundara*</i>	28
11.15 – 11.30	Transmissible Venereal Tumor in a 4-month-old Puppy: A case report. <i>I. K.L.A Ishara., H. Ariyaratna and E.M.K.A Thilakarathna</i>	29
11.30 – 11.45	Intestinal lipogranulomatous lymphangitis in a German Shepherd dog: A case report. <i>G.A.D.K.K. Gunathilaka, H.D.S. Hewapathirana, S. Kabilan, M.G.T.M. Prasadanie, T.M.S.K. Piyadasa, D.D.N. de Silva and H. Ariyaratna*</i>	30
11.45 – 12.00	Management of Fractures in Ruminants in a field setting using External Coaptation <i>E.M.U. Dissanayake*</i>	31
12.00 – 12.15	Multilobular tumour of bone in a dog: A case report <i>K.A.R.K. Perera*, S. Kabilan and H. Ariyaratna</i>	32
12.15 – 12.30	Mandibular Fracture Correction Using Dynamic Compression Plates in a Dog <i>S. Kabilan*, R.M.N.S. Nuwanshika, G.A.D.K.K. Gunathilaka, H.D.S. Hewapathirana, T.M.S.K. Piyadasa, H.M.S. Wijekoon and D.D.N de Silva</i>	33
12.30 - -12.45	Uncommon presentations of a common disease: Two cases of Transmissible Venereal Tumour <i>K.A.R.K. Perera*, I.P.C.S. Kithsiri, C. Abeykoon and H. Ariyaratna</i>	34

12.45 – 13.00	Combination of Surgical Correction and Platelet-rich plasma therapy for Achilles tendon rupture: Two successful clinical cases <i>H.D.S. Hewapathirana*, G.A.D.K.K. Gunathilaka, S. Kabilan, K.A.R.K. Perera, M.G.T.M. Prasadinie, T.M.S.K. Piyadasa, H.M.S. Wijekoon and D.D.N de Silva</i>	35
13.00 – 13.15	Cardiac Rhabdomyosarcoma in a Doe: A case report <i>G.M. Vidura, Y.K. Jayawardana, B.M.D.N. Kularatne, W.P.P.S.I. Perera, P.G.A.S. Palkumbura, R.R.M.K.K. Wijesundara, P.G.A. Pushpakumara and G.D.R.K. Perera*</i>	36
13.15 – 13.30	Multiple Trichoepitheliomas in a Cross-bred Dog: A case report <i>W.M.N.S. Wijesooriya*, S. Kabilan, H.M.S. Wijekoon, K.K. Wijesundera, P.G.A.S. Palkumbura and H. Ariyaratna</i>	37
13.30 – 13.45	Recurrent Sub-cutaneous Spindle Cell Tumour with Histological features consistent with a Peripheral nerve sheath tumour in a 5-months-old mixed-breed dog: A case report <i>T.M.S.K. Piyadasa, S. Kabilan, N.B. Ramesh, H.D.S. Hewapathirana, R.M.N.S. Nuwanshika, G.A.D.K.K. Gunathilaka, A.T. Liyanage and H. Ariyaratna*</i>	38
13.45 – 14.00	Immune-mediated Haemolytic Anaemia in Dogs: A One-year Retrospective Survey at the Veterinary Teaching Hospital, Peradeniya <i>B.M.L.N. Bandaranayaka*, K.A.R.K. Perera, E.R.K.V. Edirimanne, D.R.A. Dissanayaka and H. Ariyaratna</i>	39
14.00 – 14.15	Cytological Diagnosis of a Sinonasal carcinoma in a German Shepherd Dog: A case report <i>W.M.N.S. Wijesooriya*, W.R.J.P. Walpola, A.T. Liyanage, A. Dangolla, D.D.N. De Silva, H.M.S. Wijekoon and H. Ariyaratna</i>	40
Day 02 - 23 rd October 2021- Parallel Sessions Technical Session IV – Clinical Session (14.30 – 18.00)		
Session Chair – Dr. Suranji Wijekoon		
14.30– 14.45	Cutaneous Asthenia (collagen dysplasia) in a Rottweiler <i>K.A.R.K. Perera*, T. Apinaiyaa, K.A.N. Wijayawardhane, H.M.S. Wijekoon and D.D.N. de Silva</i>	41

14.45 – 15.00	Soft Tissue Sarcomas in dogs: Two case reports <i>B.M.L.N. Bandaranayaka*, W.R.J.P. Walpola, A.T. Liyanage, T.M.S.K. Piyadasa, C. Abeykoon, H.M.S. Wijekoon, E.R.K.V. Edirimanne and D.D.N. de Silva</i>	42
15.00 – 15.15	High Grade Sarcoma of the Maxilla in a one-year-old Labrador Retriever: A case report <i>A.T. Liyanage*, W.M.N.S. Wjesooriya, T.M.S.K. Piyadasa, W.P. Walpola, H. Ariyaratna, H.M.S. Wijekoon and D.D.N. de Silva</i>	43
15.15 – 15.30	Intestinal Phytobezoar in a Goat: A case report <i>B.M.D.N. Kularatne, B.I.U. Perera, G.M. Vidura, Y.K. Jayawardana, H.E.L. De Seram, P.G.A. Pushpakumara and G.D.R.K. Perera*</i>	44
15.30 – 15.45	Tetanus in a dog – Successful outcome of the treatment: A case report <i>B.R.Nirujan, S. Kabilan and K.A.N. Wijayawardhane*</i>	45
15.45 – 16.00	Effect of Intra-articular injections of Platelet Rich Plasma (PRP) for Lameness in Dogs with Osteoarthritis of the Coxofemoral Joints <i>M.G.T.M. Prasadinie*, H.D.S. Hewapathirana, D.D.N de Silva and H.M.S. Wijekoon</i>	46
16.00 – 16.15	Possible Breed Predisposition in Vestibular Syndrome (Vs) using data collected at Veterinary Teaching Hospital, Peradeniya <i>E. Bernard and A. Dangolla*</i>	47
16.15 – 16.30	Concurrent occurrence of High-Grade Mast Cell Tumour and Hepatoid Gland Adenoma in a young male Labrador Retriever <i>W.R.J.P. Walpola*, K.A.R.K. Perera, H.D.S. Hewapathirana, I.P.C.S. Kithsiri, A.T. Liyanage, S.U. Abeyrathne, H.M.S. Wijekoon and D.D.N. de Silva</i>	48
16.30 – 16.45	Enucleation of a ‘Khilari’ Bull under the Field Condition: A Rare Case of Lacrimal Gland Neoplasia <i>W.P.P.S.I. Perera, W.M.T.D. Ratnakumara, P.G.A.S. Palkumbura, R.R.M.K.K. Wjesundara, G.D.R.K. Perera* and A.A.A.W.K. Amarasinghe</i>	49
16.45- 17.00	A Case of Chronic Urinary Retention <i>S.U.G. Amarasena, K.A.N. Wijayawardhane*, D.D.N de Silva and H.M.K. Dananjaya</i>	50

17.00 – 17.15	Antimicrobial Resistant Pattern of <i>Staphylococcus</i> Species Isolated from Canine Pyoderma <i>M.L.W.P. De Silva, K.S.A. Kottawatta, R.S. Kalupahana, P.G.A.Pushpakumara, C.B. Riley and K.A.N.Wijayawardhane*</i>	51
17.15 - 17.30	Management of Septic Peritonitis in Dogs and Cats: Primary Closure Vs Open Peritoneal Drainage <i>H.K.U.S. Hemachandra* and D.M. Siriwardhane</i>	52
17.30 – 15.45	Treatment trial for Non-Responsive Anemia with Surgical Removal of Retained Ovaries: A case study <i>H.K.U.S. Hemachandra*</i>	53

Day 02 - 23 rd October 2021- Parallel Sessions		
Technical Session V – Animal Production Session (09.30 – 12.15)		
Session Chair – Dr Chanaka Rabel		Page No
10.30 – 10.45	Effects of Fermented Juice of Epiphytic Lactic Acid Bacteria (FJLB) on Fermentation Quality of Maize Silage <i>M.W.D.C. Weerathunga*, U.W.G.D.N. Udagama, M.P.B. Kumara Mahipala and W.M.P.B. Weerasinghe</i>	54
10.45 – 11.00	An Oestrus Synchronization Protocol Using 17-A-Hydroxyprogesterone Caproate (Proluton) on the Pregnancy Rate of Goats <i>S. Premaratne¹ T. De Silva, L. Fonseka, R. Sampath, K.M. Wimalasooriya, D. Wickramasinghe, K. Premarathne, A. Olagedara, C. Gajaweera, S. Disnaka, I. Pathirana*</i>	55
11.00 – 11.15	Use of Vestibular Cytology as an Indicator for Estrous Detection and Artificial Insemination in Crossbred Goats <i>M.B.D. Lakmalie, G.D.R.K. Perera, R.M.C. Deshapriya, D.M.S. Munasinghe and R.M.S.B.K. Ranasinghe*</i>	56
11.15 – 11.30	Effect of Climate and Management Conditions on Production Parameters of Selected Commercial Layer Strains <i>N.M.I.D. Karunadasa and C.M.B. Dematawewa*</i>	57
11.30 – 11.45	Effect of Egg Size and Flock Age on Post-hatch Weight of Day Old Chicks of Village Chicken (<i>Gallus gallus</i>) <i>U.G.V.S.S. Kumara, C.M. Keerthirathne, M.M.D.D. Bandara, A.B. Amunugama, M.B.D. Lakmalie and L.G.S. Lokugalappatti*</i>	58
11.45 – 12.00	Artificial Insemination of Sheep in Sri Lanka: A Successful Preliminary Study <i>S. Premaratne*, S. Kalubowila, C. Kannangara, S. Disnaka, G.D.R.K. Perera and M.P.S. Magamage</i>	59
12.00 – 12.15	New Dimensions of Swine Breeding through Artificial Insemination in Sri Lanka <i>S. Premaratne*, S. Disnaka, G.D.R.K. Perera and M.P.S. Magamage</i>	60
12.15 – 13.15	LUNCH BREAK	

Day 02 - 23 rd October 2021- Parallel Sessions		
Technical Session VI – Wildlife and Aquaculture Session (13.15 – 16.15)		
Session Chair – Dr. Ganga Wijesinghe		Page No
13.15 – 13.30	A case report of Parasitic Co-infection in Goldfish (<i>Carassius auratus</i>) <i>H.M.M. Madushani, D.M.W.C.J. Dissanayake and D.P.N. De Silva*</i>	61
13.30 – 13.45	Growth Performance and Survival of Indian Major Carp <i>Catla catla</i> Post larvae Fed with Different Density of Freshwater Zooplankton <i>Daphnia magna</i> <i>P.A. Sanduni Madhushani, M.N.M.Fouzi* and P.M. Withanage</i>	62
13.45 – 14.00	Systemic Aspergillosis in a Captive Newly Hatched Emu Chick (<i>Dromaius novaehollandiae</i>) <i>P. Ediriwarne, I. Rathnayake, A. Palkumbura, T. Gunawardena, C. Rajapaksha, R. Jinadasa and K. Wijesundera*</i>	63
14.00 – 14.15	High Occurrence of Multi-drug Resistance among Gram-Negative Bacterial Pathogens in Freshwater Ornamental Fish <i>D.M.P.M. Dhanapala, R.S. Kalupahana, A.W. Kalupahana, D.P.H. Wijesekara, K.S.A. Kottawatta, N.K. Jayasekera, A. Silva-Fletcher, S.S.S.de S. Jagoda*</i>	64
14.15 – 14.30	Parasitic Dinoflagellate, <i>Hematodinium</i> spp. as a Cause of Heavy Mortality in Cultured Mud Crab (<i>Scylla serrata</i>) in Sri Lanka <i>R.M.I.M. Rathnayake, R. M. N. P. K. Ranathunga, A.W. Kalupahana, G.S.P.de S. Gunawardena and S.S. S de S. Jagoda*</i>	65
14.30 – 14.45	Detection of Infectious Spleen and Kidney Necrosis Virus (ISKNV) Infection in Freshwater Ornamental Fish from Two Provinces of Sri Lanka <i>D.M.P.M. Dhanapala, R.M.I.M. Rathnayake, D.M.S.G. Dissanayaka, R.R.M.K.K. Wijesundera, A.W. Kalupahana and S.S.S de S. Jagoda*</i>	66
14.45 – 15.00	Mortality, Rescue and Release Statistics of <i>Panthera pardus kotiya</i> in Central Hills of Sri Lanka during 2019 and 2020 <i>M. A. Pinidiya*, V.P.M.K. Abewardhana, B.D.S. Jayawardhana, G.A.T. Prasad, C.G. Wijesinghe, R.R.M.K.K. Wijesundara and L.G.S. Lokugalappatti</i>	67
15.00 – 15.15	Insights into Research on Infectious Diseases in Ornamental Fish and Cultured Food Fish in Sri Lanka: Trends and Gaps <i>D. Gunaratne and E. Pathirana*</i>	68
15.15 – 15.30	Occurrence of <i>Paradujardinia halicoris</i> in a Dead <i>Dugong dugon</i> in Kilinochchi, Sri Lanka <i>P.G.I.D. Amarasiri*, M.D.S. de Silva, B. Giridharan, R. Gowrithilagan, A.M.H. Atapaththu and N.C. Gamagedara</i>	69

73rd Annual Scientific Sessions of Sri Lanka Veterinary Association

15.30 – 15.45	A Retrospective Analysis of Ornamental Fish Submissions to a University-Based Fish Disease Diagnostic Laboratory <i>R.M.I.M. Rathnayake, D.M.P.M. Dhanapala, K.L.N. Ananda, A.W. Kalupahana and S.S.S de S. Jagoda*</i>	70
15.45 – 16.00	Evaluation of the Nutritional Composition of Suckermouth Armoured Catfish (<i>Pterygoplichthys disjunctivus</i>) Collected from Reservoirs in Sri Lanka <i>W.M.L.A. Wanasinghe, M.N.M. Fouzi*, L.G.S. Lokugalappatti, H.B.S. Ariyaratne and M.W.C.D. Palliyeguru</i>	71
16.00 – 16.15	Evaluation of Export Performance of Ornamental Fish Industry in Sri Lanka <i>U.S Gunarathna*, C.S Gangani and L.M. Abeywickrama</i>	72

Keynote Speech

Transboundary Animal Diseases and Role of Veterinarians

Dr. Aruna Ambagala

(BVSc, MSc, PhD)

**Head of the mammalian diseases unit and the OIE Reference Laboratory for Classical Swine Fever at the National Center for Foreign Animal Disease (NCFAD), Winnipeg, MB, Canada
Adjunct Assistant Professor, University of Calgary, Calgary, Canada**



Adjunct Professor, University of Manitoba, Winnipeg, MB, Canada

Transboundary Animal Diseases (TADs) are contagious or transmissible, epidemic diseases, with the potential to spread rapidly across the globe and the potential to cause substantial socioeconomic and public health consequences. They threaten the global food supply by direct loss of animal proteins such as meat, milk and eggs, and hides, wool, and also animal power and through loss of human productivity in the case of zoonosis. Across the globe, increased demand for animal protein has resulted in the emergence of increasingly complex livestock systems and back yard farms that has inadequate biosecurity. In these systems, animals are primarily selected on production traits rather than their disease resistance. The accompanying increase in enhanced biosecurity measures on farms has also increased vulnerability of livestock to disease threats, as the animals in these farms are immunologically naïve and thus at increased risk from pathogen incursions. Increased global transportation of livestock and livestock products for trade, increased international travel, changes to forest ecology, climate change and global warming and increased conflicts and unrest in developing countries have contributed to the global spread of TADs reaching epidemic proportions.

Prevention and successful management of TADs requires a number of interlocking elements, foresight, prevention. Early detection and swift and effective reaction, and collaboration at the local, national and international level. In this process, veterinarians play a critical role. Today's veterinarians are highly educated and trained to protect the health of both animals and people from emerging TADs and zoonosis.

All TADs are reported to the OIE, and African swine fever (ASF) is one of the most reported diseases to the OIE over the last couple of years. ASF is a contagious hemorrhagic viral disease of domestic and wild pigs. Until 1957, ASF was restricted to sub-Saharan Africa. ASF spread to Portugal in 1957 when pigs near Lisbon airport were fed waste from an airline flights. The virus spread to Portugal, Spain, Italy, France, Belgium and the Netherlands, and later Brazil and Caribbean. With the exception of Sardinia, the disease was eradicated but in Sardinia it has remained endemic since its introduction in 1982. ASF was reintroduced to Europe through Georgia in 2007, and then it spread slowly but steadily in Russia and Europe. Later it spread to China and South East Asia, India, and most recently into Dominican Republic and Haiti. ASF poses a significant risk to the health of the Canadian swine herd, the pork industry and the Canadian economy. The Canadian National Reference Laboratory for ASF at the National Centre for Foreign Animal Disease, (NCFAD) Winnipeg, MB has state-of-the-art molecular, serological, and virological diagnostic assays for detection and confirmation of ASF. NCFAD continues to improve the existing diagnostics and develop new diagnostic tools. Results from ongoing research projects on evaluation and validation of field deployable, portable diagnostic assays and alternative sample types for ASF surveillance will be discussed.

Plenary Speech-Animal Health Session

Procedures adopted by Public Health Veterinary Service of the Ministry of Health in control & Eradication of Rabies in Sri Lanka

Prof. Ashoka Dangolla (BVSc, Dip Vet Epid, PhD)

Department of Veterinary clinical science,

Faculty of Veterinary Medicine and Animal Sciences, University of

Peradeniya, Sri Lanka. Honorary Director of Ministry of Wildlife

Conservation and Forestry, WHO Veterinary Consultant



The annual human death rate due to rabies, a neglected tropical disease, has been decreasing in Sri Lanka, with numbers remaining stagnant at around 30. Effective human anti-rabies post exposure treatment has been attributed to this success. Rabid dogs, owned either totally, partially or are completely stray, are to be blamed though reactivation of sylvatic cycle is also a factor. We are not looking to eliminate stray dogs altogether, instead maintaining a healthy, vaccinated, and manageable street dog population is the focus. Given bi-annual breeding, a relative short life span on the streets and abandonment of hormonal birth control in stray dogs, there needs be an effective, rapid and impactful dog vaccination and a spay-neuter program implemented. However, when a dog bite victim reaches a 24hour anti-rabies vaccination clinic, this information reaches the district rabies public health inspector (PHI). He would investigate the matter and undertake to vaccinate all the dogs in the area concerned (known as ring vaccination). The district rabies PHI, the key person, works with regional epidemiologist (RE) guided by the regional director of health services (RDHS) and under coordination of Public Health Veterinary Service (PHVS) of the Ministry of Health. This ring vaccination is in addition to the annual, strategically pre-planned, mass vaccinating clinics, approximately 2km apart, done after much publicity among the public. Mass vaccination clinics take a full year to cover the entire district with respective PHIs in areas operated under the medical officer of health (MOH). If all human and logistic resources are adequate, the district rabies PHI would do a MOPU UP vaccination with an auto plunger (auto vaccinator) 2-5 days after mass point vaccination to include any dog missed though stray dog catching is not done. Given the low priority assigned to rabies, most human and logistic resources within the pool are not dedicated to rabies and the current COVID pandemic has negatively impacted the dog rabies vaccination program. Since public gatherings are discouraged, in addition to mass vaccination points, the vehicle publicizing the vaccination point at times can also take on the role of administering the vaccination itself, often undertaking the process on roadsides when required. It must be noted, that in some districts human deaths due to rabies have not been reported for over 2-3 years though dog rabies is prevalent in the district.

The dog population is estimated using 1:8 (dog: human) ratio by the district rabies PHI, without on ground surveillance. Most dogs in cities are vaccinated by government or private practicing veterinarians while 11 local government bodies with their respective veterinary surgeons also vaccinate dogs. More than 10 dog welfare nongovernmental organizations (NGOs) currently carry out vaccination and spay-neuter programs according to their own schedule in various parts of the country. Only one of them, and not the Ministry of Health, uses a GPS based software for proper street dog survey in an identified PHI area. They catch dogs using nets, perform spay-neutering, vaccinate, and release the dogs. In Sri Lanka, there has been no proper national strategy on rabies control, a rabies control technical committee has not been operational, integrated bite case management is not implemented and the World Organization for Animal Health (OIE) is not notified when cases according to the animal rabies definition is identified. Poor coordination among institutes involved and weak data management is also noticed.

Laboratory rabies diagnosis must be strengthened and regional laboratories with quick diagnostics must be established. Identification of rabid dogs, detention, euthanasia, decapitation, storage and transportation of heads and the occipital foramen technique, need discussion and attention. In addition, education, communication, public awareness and advocacy need better attention. Universities under the one-health concept must undertake practical and useful research projects with proper coordination with the PHVS. Legislation, the Rabies Act, Dog Registration Ordinance, Animal Welfare Act, Animal Diseases Ordinance, and the Nuisance Ordinance, though extremely old, clearly indicate the significant role of local governments and responsible dog ownership in this regard; both of which are poorly implemented. The weak involvement of the Department of Police, though legally bound, is relatively insignificant according to the Police Ordinance.

Prof. Subhashinie Kariyawasam
(BVSc, PhD, DACVM, DACPV, DACVPM, DABMM)

Professor of Microbiology
Chair, Department of Comparative, Diagnostic and Population Medicine,
University Florida
College of Veterinary Medicine,
University of Florida, USA.



Antimicrobial resistance (AMR) is a complex and multifaceted crisis that threatens human and animal health at unprecedented levels on a global scale. The emergence of AMR is an inevitable consequence of the evolutionary adaptation of microbes, driven by the use, overuse, and abuse of antimicrobial agents in human, animal, and environmental sectors. Other drivers include the spread of resistant organisms and resistance determinants resulting from poor infection control practices, environmental contamination, and geographical movement. In recent years, AMR has led to the increasingly rapid and prevalent emergence of resistance in a range of pathogenic and commensal bacteria. This threat has the potential to undermine the treatment of many infectious diseases. The magnitude of impact is unknown due to the lack of quantitative evidence for the level of resistance transmission occurring between livestock and humans. However, in veterinary medicine, the use of large quantities of antibiotics in livestock for growth promotion of food animals is believed to contribute to the trending emergence and spread of bacteria with antibiotic-resistant traits.

Transmission of antimicrobial-resistant bacteria or AMR determinants from food-producing animals to humans can either be directly acquired through contact with those animals or indirectly acquired through the food chain or exposure to contaminated environmental niches, such as manure, wastewater, and agricultural land. The foodborne threat of AMR in low and middle-income countries is extremely concerning, due to pressures of increasing demand for animal protein sources in those countries, as well as a lack of systems to monitor and track AMR organisms in animals. Other sources of AMR in these geographical areas include a largely unregulated pharmaceutical market, drugs used without professional oversight, and poor diagnostic techniques. These issues indicate a need to mitigate AMR at a global scale, using a collaborative One Health approach, considering human, animal, and environmental health partners. In this endeavor, the role of veterinarians is critical to serve as advocates for the animal agriculture industry. Veterinarians must retain access to the essential medications required to protect animal health and welfare while recommending measures to curtail AMR persistence and emergence. They share and contribute to the ultimate goal of improving human, animal, and environmental health.

The primary concerns relevant to the animal agriculture sector are the long-term use of medically important antimicrobials in feed for growth promotion and mass medication with antimicrobials such as third-generation cephalosporins and fluoroquinolones, which are critically important for humans. Veterinarians' roles in combatting AMR include formulating regulations and policies to increase veterinary oversight, provide stewardship to ensure judicious use of antimicrobials, and enhance surveillance to track AMR in pathogenic and commensal bacteria. They must also maintain farm records to understand the extent and nature of antimicrobial use, analyze diagnostic reports to determine resistance patterns of common bacterial pathogens, report unusual or significant AMR patterns to relevant authorities, and improve on-farm infection control practices. Additional roles include developing farmer education programs to raise awareness, exploring alternatives to conventional antimicrobial agents, and improving animal husbandry methods to reduce food animal diseases. In recent years, due to concerted efforts by national and international regulatory agencies to combat AMR, many developed nations have initiated action plans and taken steps to ban the use of medically important antimicrobials for growth promotion while insisting that there should be strict veterinary oversight on antibiotic use and prescription. On the positive side, there is ample evidence to suggest that antimicrobial use in food animals can be restricted without any adverse impact on income, animal health, and welfare.

Plenary Speech- Clinical Session

**Diagnostic approach to lumps and bumps in small animal clinical practice:
A Pathologist perspective**

**Dr. Neil Horadagoda,
(BVSc, MVSc, PhD, MANZCVS, FSLCVS)
Veterinary Pathologist, Veterinary Teaching Hospital,
Camden, University of Sydney, Australia.**



Admittedly, infectious diseases particularly those caused by haemoprotozoan parasites, their diagnosis, treatment, and management constitute a major component of small animal practice in Sri Lanka. Skin diseases have also been highlighted as an important part of clinical practice and over the years, several studies have described their incidence, presentation, and clinical progression. Tumours of the skin are recognised as one aspect of these dermatological pathologies and the occurrence of these entities are often reported as single or case series. At this year's scientific sessions of the Association, I have noted that several hitherto unreported as well as unusual presentation of skin tumours are being discussed. Hence, I considered it relevant to review the diagnostic approach of skin masses in this presentation from a practical perspective so that practitioners may acquire the confidence and an approach to some basic skills which they can almost directly establish and implement with minimal cost implications. Apart from those engaged in clinical practice, the presentation will attempt to provide information to veterinarians involved in diagnostic laboratory work in veterinary hospitals, located particularly in urban areas.

The detection of a skin tumour is often noted by the owner during grooming or bathing of a pet and is brought to the attention of the practitioner. On the other hand, a skin mass may be detected by the practitioners during a routine health check-up or at annual vaccination. The mass would then be evaluated in terms of the signalment, gross findings and growth pattern. In the first part of this presentation, I will discuss the use of fine needle aspiration (FNA) in cytology, a rapid, inexpensive, relatively easy and a point of care diagnostic approach which I believe every practitioner should be familiar and competent with. The talk will focus on sample collection using FNA, slide preparation, processing, staining, microscopic examination, and a brief approach to interpretation into the categories of inflammation, hyperplasia, or neoplasia, or a combination of these categories. The information provided will be supported with direction to literature accessible through the internet and other sources.

The second part of the talk will focus on histopathology which is considered the gold standard in tumour diagnosis. This would entail the collection of a tissue sample through a biopsy, which may be incisional or excisional. Tumour margins will be discussed in brief, and the types of biopsies will be reviewed using examples. The talk will focus on proper sample preparation, fixation, together with safety and care related to dispatch of specimens to a laboratory. One of the key aspects in obtaining a proper diagnosis whilst helping the pathologist in this process is based on the paperwork which accompanies the samples. Standard specimen submission forms will be discussed with a summary of dos and don'ts.

Implementing the Appropriate Reproductive Biotechnologies-The Fast Lane towards Self-Sufficiency in Dairy Products

Prof. Matthew B. Wheeler

(B.S, MS, PhD, NIH Fellow, NIH NRSA Fellow)

Professor of Biotechnology and Developmental Biology Department of Animal Sciences, Department of Bioengineering, Department of Veterinary Clinical Medicine, Carl R. Woese Institute for Genomic Biology (Regenerative Biology and Tissue Engineering), Beckman Institute for Advanced Science and Technology Carle-Illinois College of Medicine, Urbana, Illinois, USA.



The current world population of 7.9 billion has been projected to swell close to 10 billion by the year 2050. One of the leading questions among the dozens of questions raised by this 20% population expansion, is “how do we feed this population?”. Expansion of arable land is obviously not the right answer. Then what is? Providing a comprehensive answer to this question is beyond the scope of this paper; however, one thing is for certain; that is production needs to be made more efficient, be it milk, meat, eggs, agricultural produce, offspring, or automobiles.

Optimal use of reproductive biotechnologies is no doubt a critical piece of the puzzle to improving efficiency of not only livestock reproduction but also livestock production.

The University of Illinois' 'Tropical-Adapted Cattle Project' is on a mission to optimize dairy cow production and reproduction in developing countries by helping them establish suitable dairy breeds i.e. Gir, Gir X Holstein, Gir X Jersey crosses. A pilot project is underway at a dairy cattle farm in South Carolina, USA, utilizing cutting-edge reproductive biotechnologies such as Multiple Ovulation and Embryo Transfer (MOET), Ovum-Pick Up (OPU), In Vitro Maturation (IVM), In Vitro Fertilization (IVF) and Embryo Culture (EC) as well as Fixed-Time Artificial Insemination (FTAI) to establish nucleus herds-suitable for tropical climates. –

Having subjected 40 donor animals to the above reproductive biotechnologies, to-date, we have produced high genetic-merit heifers, cows, and bulls from the following pure breeds and crossbreds.

- Purebred Gir
- 1/2 Holstein X Gir
- 3/4 Holstein X Gir
- 3/4 Gir X Holstein
- Girolando (5/8 Holstein X 3/8 Gir).

Out of the above animals, to-date, only 1/2 Holstein X Gir have completed lactation. Supported on a 100% pasture diet, these 1/2 Holstein X Gir cows (N=5 cows) have averaged 17-22 liters/day over their first two lactations under conditions similar to those of the tropics (33-35°C and 90% humidity). First lactation data from Girolando heifers will be available starting November 2022. A total of ~350 Girolando calves will be born by April 2022.

I am confident that a similar model utilizing reproductive biotechnologies can place Sri Lanka in the fast lane towards self-sufficiency in dairy products.

Role and Challenges of a Wildlife Veterinarian

Dr. Tharaka Prasad ((BVSc, MSc, Dip. Wildlife Management)

Director- Wildlife Health

**Department of Wildlife Conservation and Forestry,
Sri Lanka**



Routine activities of wildlife veterinarians (zoo and wildlife) include clinical management of sick or injured wild animals in the wild or under captivity until recovery, population control of problematic wild animals, translocation of problematic wild animals, rehabilitation of orphan wild infants and disease surveillance with services for in-situ or ex-situ conservation.

Wildlife health carries great importance as it plays a major role in the One Health program and is of economic importance to the country, as a main source of income generation via eco-tourism activities. It also helps reduce issues within human-wildlife conflicts and other related problems. Further, since, this field is quite diverse and is constantly evolving into new areas within the veterinary field, it has the potential to attract a younger generation of veterinarians with novel techniques.

Global disease prevention, management and control efforts must recognize the interdependent relationship between animal and human health. This is the approach known as ‘One Health.’ This ensures healthcare researchers and practitioners in both areas work hand-in-hand to prevent disease outbreaks across species and address the root cause of their spread. This has led to the successful management of many deadly zoonotic diseases and is being used to eliminate potential new outbreaks in future.

Wildlife provides stability to different processes of nature. The importance of wildlife can be categorized as ecological, economical, and investigatory whilst also playing an important role in conserving biological diversity, etc. On the other hand, risks from wildlife are also increasing with increased global trade, global warming and changes in human behavior, all of which provide multiple opportunities for pathogens to find new territories and evolve into new forms.

When considering World Health, we know that 60% of pathogens that cause human diseases come from domestic animals or wildlife, and 75% of emerging human pathogens are of animal in origin. Also 80% of pathogens that are concern with bioterrorism are of animal origin. We are working to achieve a more sustainable future for our animal species and others. We examine ecological health issues from various standpoints, including its emergence, re-emergence and resurgence in infectious diseases. In addition, we also focus on the increasing biological effect of toxic chemicals, habitat alterations such as habitat fragmentation and degradation, loss of biodiversity and ecosystem services and global climate and atmospheric change.

Conservation medicine requires professionals from diverse disciplines to work together in addressing the complex aspects of the intersection of health and the environment. The decline in ecological health is happening at all scales; from the global to the local. It affects all terrestrial, marine and freshwater environments.

Our mandate as wildlife veterinarians is to maintain ecological health and prevent the extinction of wild animals.

Pentosan Polysulfate Regulates Heparin 1-Facilitated Formation and Function of Osteoclasts Derived from Canine Bone Marrow

S. Wijekoon^{1*}, T. Sunaga², Y. Wang², C. Mwale², S. Kim² and M. Okumura²

¹*Department of Veterinary Clinical Sciences, Faculty of Veterinary Medicine and Animal Science, University of Peradeniya*

²*Laboratory of Veterinary Surgery, Department of Veterinary Clinical Sciences, Faculty of Veterinary Medicine, Kita18, Nishi9, Kita-ku, Sapporo, Hokkaido 060-00818, Japan*

*Corresponding author: suranjisk@gmail.com

Hepcidin, the crucial regulator of iron homeostasis, is produced in the liver in response to anaemia, hypoxia, or inflammation. Recent studies have suggested that hepcidin and iron metabolism are involved in osteoporosis by inhibiting osteoblast function and promoting osteoclastogenesis. Pentosan polysulfate (PPS) is a heparin analogue and promising novel therapeutic for osteoarthritis (OA). This study was undertaken to determine whether PPS inhibits hepcidin-facilitated osteoclast (OC) differentiation and iron overload. Canine (n=3) bone marrow mononuclear cells were differentiated to OC by macrophage colony-stimulating factor and receptor-activator of nuclear factor kappaB ligand with the treatment of hepcidin1 (200, 400, 800, 1200 nmol/L) and PPS (1, 5, 10, 20, 40 µg/mL). Differentiation and function of OC were accessed using tartrate-resistant acid phosphate staining and bone resorption assay while monitoring ferroportin1 (FPN1) and iron concentration by immunocytochemistry. Gene expression of OC for cathepsinK (CTK), matrix metalloproteinase-9, nuclear factor of activated-T-cells cytoplasmic 1 and FPN1 was examined. Hepcidin1 showed a significant enhancement of OC numbers at 800 nmol/L ($p<0.01$). PPS impeded hepcidin-facilitated OC at 1, 5 and 10 µg/mL and reduction of resorption pits at 5 and 10 µg/mL ($p<0.01$). All OC specific genes were downregulated with PPS, specifically in a significant manner with CAK at higher concentrations. However, heparin-induced FPN1 internalization and degradation was inhibited at higher concentrations (10, 20, 40 µg/mL) of PPS whilst restoring the iron-releasing capability of OC. We demonstrate for the first time that PPS is a novel inhibitor of hepcidin-facilitated OC formation/function, which might be beneficial for the treatment of OA and osteoporosis.

Keywords: Canine, Heparin, Osteoclast, Osteoarthritis, Osteoporosis, Pentosan Polysulfate

Measurement of Serum 5 α -pregnane-3,20-dione (5 α -DHP) and Progesterone in Female Asian elephants (*Elephas maximus*)

T. De Silva¹, I. Pathirana^{1*}, B. Bandara², L. Fonseka¹, H.P.R.N.S. Karunarathna²,
K.K. Sumanasekara² and N. Kawate³

¹Department of Animal Science, University of Ruhuna, Kamburupitiya, Sri Lanka

²Elephant Orphanage, Department of Zoological Gardens, Pinnawala, Sri Lanka

³Department of Advanced Pathobiology, Osaka Prefecture University, Izumisano, Osaka, Japan

*Corresponding author: indunilvet@agri.ruh.ac.lk

Among circulating progestins, i.e., progesterone, 5 α -pregnane-3,20-dione (5 α -DHP) and 3 α -hydroxy-5 α -pregnan-20-one, 5 α -DHP predominates, the concentrations of circulating 5 α -DHP and progesterone, and their relationship, are yet to be reported in Asian elephants. The objectives of this study were to measure circulating 5 α -DHP and progesterone concentrations in the same animal and to examine the correlation between the two hormones in Asian elephants. Five Asian elephant cows (23 – 37 years of age) were selected from the Pinnawala Elephant Orphanage, Sri Lanka and serial blood samples (n = 14 – 21 per elephant; total, n = 90) were collected from October 2019 to September 2020. Sampling was done in 1 – 3 week intervals. None of the animals showed signs of pregnancy during the sampling period. Both hormones were measured by enzyme immunoassays (EIA). The EIA for 5 α -DHP was newly established using a commercial anti-5 α -DHP polyclonal antibody (Cosmo Bio, Tokyo, Japan; cross-reactivities with 5 α -DHP and progesterone were 100 and 16%, respectively) by modifying the previously reported testosterone EIA. The detection range of the 5 α -DHP assay was 0.39 – 400 ng/mL. The intra-assay and inter-assay coefficient of variations were 14.9 and 19.3, respectively. The recovery rate of 5 α -DHP by diethyl-ether was 92.99 % (n = 4). Serum 5 α -DHP and progesterone concentrations ranged from 0.15 – 20.04 ng/mL and 0.18 – 7.17 ng/mL, respectively. There were individual variations (p < 0.05) among animals for both hormones. Mean 5 α -DHP concentrations were always higher in all elephant cows while three cows showed markedly higher (p < 0.05) 5 α -DHP concentrations (3 to 4-times) than progesterone. There was a positive correlation (r = 0.45, p < 0.01) between circulating 5 α -DHP and progesterone concentrations in elephant cows. Although 5 α -DHP and progesterone concentrations were positively correlated in female Asian elephants, mean monthly 5 α -DHP concentrations were always higher, most of the time statistically significantly, compared to that of progesterone. Further studies are being done to investigate the potential of using 5 α -DHP in pregnancy diagnosis of elephant cows.

Keywords: 5 α -pregnane-3,20-dione, Asian Elephant, Enzyme Immunoassay, Progesterone, Serum

Occurrence and Antimicrobial Resistance of Multi-Drug Resistant Extra-Intestinal Pathogenic *Escherichia coli* ST131 clone in companion animals in Sri Lanka

W.A.P.M. Dewasmika* and D.R.A. Dissanayake

Department of Veterinary Clinical Science, Faculty of Veterinary Medicine and Animal Science, University of Peradeniya

*Corresponding author: pamudimaldam@gmail.com

Global emergence and spread of extra-intestinal pathogenic *Escherichia coli* ST 131 clone has been found in both humans and companion animals. This pathogenic clone causes worldwide nosocomial and community-acquired urinary tract infection (UTI) and bacteremia. ST 131 clone, which belongs to phylogroup B2 has shown resistance to extended-spectrum cephalosporins and fluoroquinolones. However, the knowledge on the prevalence of this pathogenic clone in Sri Lanka is limited. Therefore, the objective of this study is to determine the occurrence of ST 131 clone in companion animals with the antimicrobial resistant pattern. Clinical samples were obtained from dogs and cats with extra-intestinal *E. coli* infections (UTI and endometritis) presented to the Veterinary Teaching Hospital, Peradeniya, from January 2020 to January 2021. Samples were cultured on *E. coli* chromogenic medium and subjected to biochemical testing. A total of 37 *E. coli* isolates were screened by PCR for the phylogroup by PCR for ST-specific sequence in region 19, NA114 (GenBank accession no. CP002797) for the ST131 clone. Antimicrobial resistance for 16 antimicrobial agents and production of extended-spectrum β -lactamase (ESBL) enzymes were also determined in those isolates according to EUCAST guidelines. Of the 37 isolates screened, 30 (81.08%) belonged to the phylogroup B2 of which 25 (83.33%) were ST131 and the remaining seven belonged to phylogroup A (n=1), E (n=1), B1 (n=4). Of 25 ST131 isolates tested for antimicrobial susceptibility testing, 18 were multi-drug resistant (resistant \geq 3 antimicrobial classes) with the B2 isolates were mostly resistant to ampicillin (92%) and followed by third and fourth generation cephalosporins (72%), (64%) to trimethoprim sulphonamides (64%), quinolones (56%), amoxicillin/clavulanate (40%), gentamycin (25%) and 12% were resistant to carbapenems. Of 25 ST131 isolates, five (20%) were ESBL producing isolates. Importantly, all ST131 isolates were sensitive to amikacin. The findings of the study depicted that the pandemic multi-drug resistant *E. coli* clonal group, ST131 is widely present in companion animals in Sri Lanka.

Keywords: Extra-intestinal, Antimicrobial resistance, *Escherichia coli*, Companion animals

Acknowledgement: This study was financially supported by NRC grant (19-089)

Microbiological Quality Assessment of Broiler Feed Along the Feed Distribution Chain

H.C. Gallage¹, L.A.D.E. Weerasinghe², S. Samita³, R.S. Kalupahana¹, H.M.T.K. Karunarathna¹ and K.S.A. Kottawatta^{1*}

¹*Department of Veterinary Public Health and Pharmacology, Faculty of Veterinary Medicine and Animal Science, University of Peradeniya, Peradeniya*

²*Hayleys Agriculture Holdings Limited, Colombo, Sri Lanka*

³*Department of Crop Science, Faculty of Agriculture, University of Peradeniya, Peradeniya*

*Corresponding author: sarunika@yahoo.com

Feed is an important aspect of the poultry industry as more than 70% of the total expenditure in broiler farming is spent on feeding. Various categories of feed across many brands are available in the market. The main broiler feed types are starter and finisher. The nutritional value of feed is high; thus, it can be a source of pathogens if contaminated. According to EU standards, the microbiological quality of feed should be assessed by testing for Enterobacteriaceae (ENT) (should be < 300 cfu/g) and *Salmonella* (should be free). This study aimed to investigate and compare the microbiological quality of commercial broiler feed at different stages of the feed distribution chain, namely the distribution and farm stages. The supply chain of one brand was considered and feed sampling was done at distribution and farm stages separately for starter and finisher. At the distribution stage, three feed samples were collected for each distributor, and at the farm stage, by adopting multi-stage sampling scheme, feed samples were selected from six farmers per distributor and three samples per farmer. Altogether, there were nine feed samples for each starter and finisher at the distributor stage, and at the farm stage, there were 54 samples for each starter and finisher. Each feed sample was processed for enumeration of ENT, *Salmonella* and total viable counts (TVC) as per ISO and SLSI standards. Apart from one farm level starter feed sample (ENT=330 CFU/mg), all feed samples were at the safety level of ENT and *Salmonella*. There was no significant difference ($P>0.05$) of TVC of feed among three distributors. The mean TVCs of starter feed at distributor and farm stages were 3.7×10^4 CFU/mg, and 5.1×10^4 CFU/mg, respectively. The same of the finisher feed were 1.3×10^4 CFU/mg and 5.9×10^4 CFU/mg. Analysis (ANOVA) of TVC data between distributors and farm stage showed that TVC counts were significantly different in two out of three starter distribution lines ($P=0.001$), ($P=0.021$) and one finisher line ($P<0.001$). The increase of TVC and the exceeded ENT of feed collected from farms suggests possible feed contamination at the farm level. Therefore, a source attribution study to investigate the above contamination will be helpful for safe meat production.

Keywords: Broiler feed, Microbiological Quality Assessment, Enterobacteriaceae, *Salmonella*, Total Viable Count (TVC)

Identification of Serotypes Involved in Fowl Adeno Virus (FAdV) Infections in Sri Lanka during 2018 – 2020

N. de Silva^{1*}, M. Paniago², I. Kiss³, K. Wijesundera⁴ and A. Palkumbura⁴

¹*Farmchemie Private Limited, Industrial zone, Katuwana road, 10200 Homagama, Sri Lanka*

²*Ceva Animal Health Asia Sdn Bhd, 27-2 Oval Damansara, No. 685, Jalan Damansara, 60000 Kuala Lumpur, Malaysia*

³*Scientific Support and Investigation Unit, Ceva-Phylaxia Ltd., Budapest, Hungary*

⁴*Department of Veterinary Pathobiology, Faculty of Veterinary Medicine and Animal Science, University of Peradeniya, Peradeniya, Sri Lanka*

*Corresponding Author: nalini.darshanadesilva@gmail.com

Adenoviruses are non-enveloped, double-stranded DNA viruses, belonging to the Adenoviridae family. FAdVs serotypes are associated with different diseases in poultry. Outbreaks of FAdVs have been reported recently in broiler flocks in Sri Lanka and worldwide causing economic losses. This study is carried out to identify serotypes that cause FAdV induced diseases in Sri Lanka and to discuss applicable control measures. From May 2018 to December 2020, 45 cases from suspected broiler farms distributed in major poultry producing areas, namely Western, Northwestern, North central provinces were examined. Clinical signs and lesions were recorded. Molecular detection and identification by PCR were done. 10% neutral buffered formalin fixed liver samples (13) were processed and stained with Haematoxylin & Eosin (H&E) for histopathology. Two spikes of mortality were observed in affected broilers flocks: 12-18 days and after 27 days of age respectively. Birds showed inability move, off food and water, which later developed to shivering in head, prostration, and death. Total mortality was recorded at 5% to 20%. Necropsy showed congestion and characteristic swollen, friable, pale yellowish to white liver with focal or diffuse areas of necrosis and hemorrhages. Despite hepatic lesions, Gizzard Erosions observed in 40% of the cases while ascites and hydropericardium found in 15.5%, 11% of the cases respectively. Out of 46 liver samples, nineteen (19) were positive for FAdV by PCR, representing 10 different farm locations. Serotypes 8 and 2 were identified from 5 different farm locations confirming their presence in Sri Lanka. Histopathology of all 13 samples showed characteristic microscopic lesions of FAdV infection, in particular inclusion body hepatitis (IBH), diffuse hepatocellular degeneration and necrosis and occasional basophilic intranuclear inclusion bodies. Although lesions suggestive of hydropericardium syndrome and erosions in gizzard were observed in necropsies, FAdV serotypes 4 and 1 have not been identified. Thus, effective vaccination of parent flocks against endemic FAdV serotypes is vital to prevent the disease. Inactivated FAdV vaccines containing single or multiple serotypes are widely used in other countries. Therefore, it is crucial to identify if other serotypes exist, cross-protection and prevalence in Sri Lanka to determine serotypes to be included in a vaccine.

Keywords: Fowl Adenovirus, IBH, Serotypes

Use of MIGLIS for the Separation of Sperm with High Motility in Chicken (*Gallus gallus domesticus*)

C. Priyadarshana^{1,2*}, A. Tajima³ and A. Asano³

¹Graduate School of Life and Environmental Sciences, University of Tsukuba, 1-1-1 Tennodai, Tsukuba, Ibaraki 305-8572, Japan

²Dr. Pet Hospital, 225A, Matara Road, Magalle, Galle, Sri Lanka

³Faculty of Life and Environmental Sciences, University of Tsukuba, 1-1-1 Tennodai, Tsukuba, Ibaraki 305-8572, Japan

*Corresponding Author: chathuravet@gmail.com

Sperm separation into subpopulations depending on the functional parameters is of utmost importance to improve the fertility rates of humans and animal species when assisted reproductive technologies (ART) are practised. The migration-gravity sedimentation method (MGS) was originally introduced in the early 1980s to separate sperm with high motility but with zero damage to cell structures, especially DNA, compared to the popular and established density-gradient method centrifugation (DGC). A device called MIGLIS has recently been developed and have reported that its ability to separate sperm with high motility and fertility in humans. However, there is no information on the use of MIGLIS to separate sperm subpopulations in any other animal species to date. Therefore, the objective of the study was to examine the potential use of MIGLIS for the acquisition of high motile sperm subpopulations in Chicken. When the sperm sample was placed in the outer chamber of the device and incubated at 37 °C for 60 min, we were able to recover around 10% of the sperm into the middle tube of the device. Using an Automated Sperm Motility Analysis System, we found that sperm in the middle tube was significantly different in VCL (96.65±3.06), VAP (35.79±1.32), ALH (2.49±0.09) and BCF (5.04±0.13) than the outer chamber sperm (82.80±3.43, 30.72±1.00, 1.98±0.09 and 6.50±0.30 respectively). Of note is that this method affected neither the acrosome integrity nor penetration ability of the recovered sperm. In conclusion, our results demonstrate for the first time the migration-gravity sedimentation based MIGLIS separates chicken sperm subpopulations that are with high motility from an ejaculated semen sample and would be beneficial for ART in the future. In this study, STAT Plus software (AnalystSoft Inc., Walnut, CA, USA) was used to analyse the data collected from at least four replicates of each experiment. Multiple comparisons were conducted using Tukey's honest significant difference test when normality assumptions and the equal variance were confirmed.

Keywords: Sperm, Motility, Acrosome Reaction, Assisted-Reproductive Technologies, Fowl

Management of Unusual Case of Partial Uterine Prolapse in Rhodesian Ridgeback

R.M.N.S. Nuwanshika^{*}, K.A.R.K. Perera, H.M.S. Wijekoon and D.D.N. de Silva

Department of Veterinary Clinical Sciences, Faculty of Veterinary Medicine and Animal Science, University of Peradeniya, Sri Lanka

**Corresponding Author: naduninuwanishika@gmail.com*

Prolapse of the uterus is rarely encountered in dogs. The modalities of treatment and management are decided considering whether or not the female dog is to be bred in future. The present communication is based on a case of 3-year-old 41 kg, multiparous, intact female Ridgeback admitted to the Veterinary Teaching Hospital, the University of Peradeniya with a spherical and pink mass protruding from vulva. On examination, the prolapse appeared as Type III circumferential prolapse without involvement of other structures, devoid of trauma. Manual reduction after application of topical hyperosmotic solution-Dextrose 50% failed thus, surgical intervention was proposed. As the owner strongly assured that there is no way the patient has been mated, ultrasound scanning was not done. The dog was given pre-emptive analgesic-Tramadol (SC), antibiotic-Ceftriaxone (IV), Chlorpromazine and Propofol to anaesthetize. An incision was made over the prolapse which revealed the protrusion of part of the gravid uterus and urinary bladder through a laceration of the vaginal wall. Cystocentesis was performed and the protruded part of the gravid uterus was incised ex-situ and three dead premature foetuses were removed. Next, the uterine opening was closed with a pair of bowel clamps and the animal was positioned in dorsal recumbency. A mid ventral laparotomy was performed after routine surgical site preparation. The protruded mass was pushed into the abdomen via the vagina while manipulating the mass through the laparotomy opening after removing bowel clamps. As the animal had a history of vaginal prolapse and hyperplasia and future breeding was not intended, a decision was made to perform ovariohysterectomy (OHE) upon detecting another three dead foetuses in the remaining part of the uterus. As the animal had a leukocytosis, Ceftriaxone was administered IV and prescribed with Tramadol to be given orally with the instruction of stringent wound care before discharging the patient. Follow-up examination revealed that the laparotomy incision was infected due to improper wound management by the caretaker. If a true prolapse occurs in the bitch, other organs, such as the bladder, and the uterine body and/or distal part of the colon, may be present in the prolapse. Excess ante-partum relaxation of pelvic tissues and increased intra-abdominal pressure could be the aetiology of pre-partum prolapse in the presented case.

Keywords: Pre-partum, Uterine prolapse, Laparotomy

Morphological identification of fungi isolated from poultry layer feed in the North-Western Province of Sri Lanka

D.P. H. Wijesekera^{1*}, W.D.M. Perera³, G.D.R.K Perera², S.S.S. de S. Jagoda¹ and A.W. Kaluphana¹

¹Department of Veterinary Pathobiology, Faculty of Veterinary Medicine and Animal Science, University of Peradeniya, Sri Lanka

²Department of Farm Animal Production and Health, Faculty of Veterinary Medicine and Animal Science, University of Peradeniya, Sri Lanka

³Hay Vet Laboratory, Kuliyaipitiya, Sri Lanka

*Corresponding Author: himsiya84uni@gmail.com

Fungal contamination of animal feed is inevitable in tropical countries, including Sri Lanka. It causes a reduction of the feed quality whilst certain fungi are even capable of producing toxic metabolites. Thus, consumption of such contaminated feed can adversely influence both animal and human health. Therefore, this study was conducted to isolate and morphologically identify the isolated fungi in poultry layer feed. Based on the convenience sampling method, 48 self-mixing layer feed producing farms were selected from the North-Western province of Sri Lanka. A feed sample was collected from each farm within a three-month period. Morphological characterisation was carried out following culturing on Sabouraud Dextrose Agar and Potato Dextrose Agar and staining with the lactophenol cotton blue stain. Macromorphological features (colony colour and texture) and micromorphological features (mycelial structure, fruiting head, conidiophore structure, vesicle shape, spore size and shape), were used for fungal identification. All the feed samples showed contamination with either fungi or bacteria. However, the majority of feed samples, namely 77% (37/48), were contaminated with fungi, while 23% (11/48) had only contaminating bacteria. Among 73 fungal isolates recovered from samples, *Aspergillus* species (64%) was the most frequent genus, followed by Zygomycetes (20%), *Fusarium* spp. (8%), unidentified fungi (4%), Yeast (3%) and *Penicillium* (1%). According to morphological identification, *Aspergillus flavus* (49%) was the most prevalent species among *Aspergilli*. *Aspergillus niger* (43%) was the second most abundant *Aspergilli*, while *Aspergillus terreus* (2%) and *Aspergillus parasiticus* (2%) were the least frequently isolated *Aspergilli*. The current study showed that a higher percentage of self-mixed poultry layer feed in the North-Western Province is contaminated with fungi. Moreover, the frequent isolation of mycotoxigenic fungi such as *Aspergillus* spp. (mainly *A. flavus*) and *Fusarium* spp. in self-mixed layer feed indicates the potential risk of getting mycosis and mycotoxicosis in consuming birds. Further, experiments are ongoing to detect the levels of mycotoxins in these feed samples.

Keywords: Poultry Feed, Morphological Identification, Fungi, *Aspergillus*, *Fusarium*

Acknowledgement: This study was financially supported by the University Research Grant (URG/2019/32/V) of the University of Peradeniya

Determinants of Waste Disposal Mechanisms at Household level in Colombo Municipal Council (CMC) area

E.M.U. Dissanayake^{1*} and R.C. Gamage²

¹*Government Veterinary Surgeon's Office, Mawanella, Sri Lanka*

²*Waste Management Authority of Western Province*

**Corresponding Author: udenivetdissanayake@gmail.com*

Safe disposal technologies for waste management is of paramount importance. Therefore, attention must be given to the factors that contribute to proper waste management in the geographical area of relevant local authorities. This will help to plan and implement the most effective waste management systems/procedures. Comparatively, very few studies have been conducted to determine the effectiveness of municipal solid waste management systems/ procedures in Sri Lanka. This research was carried out to investigate the factors which influence the disposal of household solid waste in the Colombo Municipal Council (CMC) area. The main objective of the study was to identify the determinants of effective waste management practices at household level of CMC area in Sri Lanka by giving special emphasis to the implementation of 3R policies, which is commonly identified as reducing waste, reusing and recycling resources and products. Further, attention was given to examine the necessity of practicing initial steps in the 7 steps of waste management at the household level. The research time period was one year, and it was performed based on analyzing information obtained from field observations, reports, literature, and a questionnaire distributed among the community and a series of focus interviews with major stakeholders. Accordingly, the research focused on investigating how household size, educational level of the household community contribute to the application of 3R policy and 7 steps of waste management and availability of disposal facilities/ services as independent variables which influence the disposal of household solid waste in CMC area. Descriptive research methodology was utilized in the research design while cluster, purposive and random sampling techniques were used to select the sample. The sample size of the study was 500 households and they were selected from 20 municipal wards, based on their geographical location. A questionnaire which comprised of double barrel and open ended questions was used as the main instrument for collecting data for this study. Based on the correlation analysis, the study found that there is a positive relationship between independent variables (size of household, educational level of the household community related to application of 3R policy and 7 steps of waste management and disposal facilities/services) and dependent variable (disposal of household waste). Accordingly, the authors found it necessary to empower and raise awareness of the importance of implementing 3R policies as well as adopting initial 7 steps of waste management at the household level. Further, it was noted that the legislative enactments (currently used old Ordinances and Acts) also need to be updated/ amended to meet the current waste disposal requirement.

Keywords: Colombo Municipal Council, Waste management systems, Disposal facilities, 3R policies, Seven steps of waste management.

A Case Report on Paralytic Ileus in a Dog Presented to Veterinary Teaching Hospital

S.A.C.H. Rodrigo¹, S.U.G. Amarasena², T.M.S.K Piyadasa², D.R.A. Dissanayaka² and D.D.N. de Silva^{2*}

¹*Department of Veterinary Pathobiology, Faculty of Veterinary Medicine and Animal Science, University of Peradeniya, Sri Lanka*

²*Department of Veterinary Clinical Science, Faculty of Veterinary Medicine and Animal Science, University of Peradeniya, Sri Lanka*

*Corresponding Author: niranjlad@yahoo.com

Paralytic ileus is a secondary condition which results from temporary and reversible obstruction in the intestines caused by interference with bowel motility due to some other disease or condition affecting motility of intestine. A 6-year-old, 32.5 kg Labrador retriever male was presented to Veterinary Teaching Hospital, University of Peradeniya, with the complaint of gradual loss of appetite and intermittent vomiting for one month. The dog had not defecated properly for three weeks. The general clinical examination revealed pale pink mucous membranes, enlarged gas filled abdomen and mild abdominal pain on palpation. Differential diagnosis included foreign body obstruction, paralytic ileus, and mega colon. No significant findings were observed in blood, serum biochemistry and electrolytes analyses. The abdominal radiography and ultrasound scanning revealed a severely distended (gas filled) small intestine with thickened wall and no foreign bodies were visible. The condition of the patient was tentatively diagnosed as paralytic ileus. The contrast abdominal radiography revealed accumulated ingesta in the stomach soon after the dog was fed with contrast solution. After one hour the content was dispersed throughout the small intestine. Even though, cause of paralytic ileus could not be determined, symptomatic treatment was started with omeprazole (1mg/kg, sid, IV), ondansetron (0.5mg/kg, bid, IV), lactulose enema and fluid therapy but an improvement was not evident after two days. Thus, it was decided to perform an exploratory laparotomy. The above treatment plan was continued further to prepare the dog for the surgery. After taking the proper pre-operative measures, the abdominal cavity was approached. Upon exploring, severely distended small intestines and hardly detectable peristalsis were evident. Greenish thick intestinal contents were removed using suction and slight peristalsis movement was then observed. Partial stenosis was found in the distal ileum close to ileo-cecal junction. The intestine was transected proximal to the stenosis and the distal opening was sutured as a *cul de sac*. The proximal opening was anastomosed with colon bypassing stenosed area and ileo-cecal junction. After the surgery, the dog was given proper postoperative care. However, unfortunately, the dog died during recovery. The diagnostic efforts of paralytic ileus should be aimed at finding the underlying cause, but it may be difficult in some animals. Identifying the primary cause, timely medical and surgical intervention and proper pre and post-surgical care carries an equal importance for the resolution of this disease condition.

Keywords: Paralytic Ileus, Exploratory Laparotomy, Obstruction in intestines

Application of risk analysis for the control of Megalocytivirus in ornamental fish in Sri Lanka

P. Sembapperuma* and A. Ponnusamy

Department of Animal Production and Health/ Animal Quarantine Office, Colombo

**Corresponding Author: pramodijs2013@gmail.com*

Megalocytivirus is related to severe disease in freshwater and marine water fish. The disease is of great concern due to high mortality in ornamental fish and because it can be transmitted to fish consumed as food, thus leading to severe economic losses in the aquaculture industry. Those involved in the international ornamental fish trade expect countries that they trade with to eradicate this virus. Megalocytivirus has been detected in ornamental fish exported from Sri Lanka. Subsequent outbreaks in local farms lead to the threat of losing export or foreign buyers not trading with Sri Lanka. As the Megalocytivirus will be the most important threat to the Sri Lankan Ornamental fish industry, this quantitative study was carried out to analyse the risk factors of spreading Megalocytivirus among ornamental fish farms in Sri Lanka. An extensive review of literature, unstructured interviews with industry personnel and field observations were used to identify the risk factors. A qualitative assessment based on experts' opinions was adopted to evaluate the risk factors identified in the previous step. Based on Likelihood and consequence scores in the risk matrix, the severity of risk factors were ranked. Risk Grid Matrix clearly shows that there are three critical factors (1) Routes of transmission of the disease (2) Bio-security levels of the farm (3) Distribution of aquatic population in the country. Exchange of freshwater broodstocks among fish farms, importing Megalocytivirus infected fish, disposal of Megalocytivirus affected dead fish and water from infected sources to the natural water bodies and mechanical transmission on farm equipment and vehicles and fish handlers can be considered as the major routes of Megalocytiviral transmission. Strict awareness programs should be conducted among ornamental fish farmers to encourage good bio-security provisions when purchasing broodstocks, killing or disposal of the affected stocks and disinfection of equipment and vehicles. Considerable emphasis must be placed on learning from the previous experiences with the disease in affected farms. Mapping the ornamental fish farms in the country is important as it allows to prevent affected farms from trading. National, local and site-specific assessments should be considered to identify the mechanisms of spreading the infection and the eradication methods which could be applied. Continuous re-assessment of risk must be undertaken and field information for the prevalence of disease becomes necessary for the detection, diagnosis, transmission and eradication of the infection. Revising the import regulations in ornamental fish imports is also important. Results from the risk assessment and alongside other information can be utilised by stakeholders of the industry to reach decisions and formulate policy.

Keywords: Ornamental Fish, International Trade, Megalocytivirus, Risk Analysis

Effects of Climatic Variations on Semen Volume and Concentration of Cattle and Buffaloes in Sri Lanka; a Retrospective Study

C. M. Keerthirathne^{1*} and U.G.V.S.S. Kumara²

¹ Artificial Insemination Centre, Polonnaruwa

² Veterinary Research Institute, Gannoruwa, Peradeniya

*Corresponding Author: chamiramk@gmail.com

Cross breeding with high producing cattle and buffalo breeds through Artificial Insemination (AI) has been considered as the primary breeding tool for rapid genetic improvement of local animals in Sri Lanka, and breeding bulls provide a major contribution to the livestock economy through AI. This is one of the strategies recommended by the government to improve milk production. The adaptation of animals to the tropical environment has been reduced as the genetically adapted cattle are crossbred with high producing, non-adapted breeds and it may increase the susceptibility to high thermal load. In bulls, this change magnifies the seasonal depression of quality semen production. The objective of this retrospective study was to determine whether the climatic variations has a significant effect on semen volume and concentration of five semen donor bulls (1 Murrah, 3 Girolanda, 1 Sahiwal) reared at the AI centre in Polonnaruwa, Sri Lanka. The volume and concentrations of 1616 semen doses (Murrah, n=208, Girolanda, n=1120, Sahiwal, n=288) collected during three year period (2017 to 2019) was analysed using ANOVA. The results showed that, there was a significant difference ($P<0.05$) on semen volume (ml) and concentration (million/ml) in each bull. The highest volume ($11.9\pm.41$) and the lowest concentration (1129.3 ± 68.19) was observed in Sahiwal and the lowest volume ($3.7\pm.38$) and the highest concentration (1358.1 ± 37.46) was observed in Murrah. The highest Temperature-Humidity-Index (THI) (82%) and temperature ($31\text{ }^{\circ}\text{C}$) was measured in June each year. These results showed that, though the significant climatic variation has been observed throughout the year, there is no significant effect ($P>0.05$) of ambient temperature, relative humidity and THI on semen volume and concentration. Therefore, this study concluded that the bulls at AI centre in Polonnaruwa have a tendency to maintain their semen volume and concentration even under a harsh environment. This study only focused on semen volume and concentration. In addition to these two parameters, future studies may look into motility and morphology of sperms and data on AI trials to find relationships between the climatic factors and semen quality of AI bulls under different climatic conditions with adequate sample size.

Keywords: Bovine, Heat Stress, Semen Concentration, Semen Volume, Climate

Total Aflatoxin Occurrence in Suspected Animal Feed Samples

S.S.K. Daluwatta*, H.M.A.K.H.K. Navarathna, R.A.T. Chandima, D.M.D.P. Dissanayaka, D.L. Ranathunga, R.A.I.M. Ranasingha, K.W.G.S.M. Kularathna and M.W.C.D. Palliyeguru

Veterinary Research Institute, Peradeniya, Sri Lanka

**Corresponding Author: sujivisamangakd@gmail.com*

Aflatoxins are mycotoxins produced by *Aspergillus* species which are naturally occurring and ubiquitous fungi. The toxins are produced in grains and crops stored in warm, humid, and dark environments where the fungi rapidly proliferate. Ingestion of aflatoxin-contaminated food results in aflatoxicosis and lead to serious health hazards due to its carcinogenic, mutagenic and teratogenic effects. In addition, they can have antagonistic, additive, and synergistic effects due to their interactions with each other and the nucleic acids and proteins, which can result in more detrimental effects compared to exposure to a single toxin. Total-aflatoxin (B1 B2 G1 G2) are particularly dangerous to both animals and humans, as they accumulate in body tissues, mostly in the liver. Moreover, chronic aflatoxin exposure, especially aflatoxin B1 directly affect the immune system and cause immunosuppression, mainly the cell-mediated responses, by depressing T and B lymphocyte functions and inhibiting their proliferation. Further, aflatoxin B1 and B2 is metabolized into M1 and M2 in cow's liver and secretes in milk. Hence, aflatoxin in animal feeds could be retained in animal products, causing severe health hazards to consumers. Therefore, it is a global public health concern. In particular, aflatoxin causes a major economic impact in hot, humid environments and developing countries where the feed and food regulations are yet to be strengthened. As the authorised laboratory under the animal feed act, the animal nutrition laboratory VRI, analyses feed and feed ingredients for their quality, especially feed received from the industry that is suspected of poor animal performances, as a need of sales or in manufacture's self-quality assessments. Such samples suspected for aflatoxin contamination are analysed for total aflatoxin concentration with Enzyme-Linked Immuno-Sorbent Assay (ELISA) using standard aflatoxin concentrations. To obtain an overall understanding on aflatoxin contamination, 67 complete feed and 110 feed ingredient samples submitted for chemical quality testing from 2017 to 2020 were numerically analyzed. Out of all 177 samples, 41% (73) were positive for total aflatoxin (40 complete feeds and 33 feed ingredients) and 25% (18/73) exceeded the FDA regulatory limits of 20ppb. (Sec.683.100 Action Levels for Aflatoxins in Animal Feed). The majority, 75% (55/73) of the positive samples, were within the acceptable limit. Feeding such low concentrations of aflatoxin was identified to leave no residues in the food of animal origin, thus, possible to use as animal feeds. Among the samples that contained total aflatoxin exceeding 20ppb the majority (33%) was cattle feed followed by maize (22%). A considerable percentage of coconut poonac (5%) and beer spent grain (5%) was also identified as contaminated with aflatoxin. Substantial total-aflatoxin contamination of cattle feed and cattle feed ingredients: maize, coconut poonac and beer spent grain could result in aflatoxin M1 and 2 secreted into cow milk and cause public health hazards. Therefore, routine monitoring of animal feeds and feed ingredients will help to improve feed and food safety and minimise the animal and human health hazards caused by aflatoxins.

Keywords: Total-Aflatoxin, Animal Feed, Food Safety, Public Health Hazards

Dairy Cattle Importation Project of Sri Lanka: Eight Recommendations to Avoid Falling into the Same Hole Again

R.A.C. Rabel^{1*}, S.P. Gunarathne¹, M. Hanifa², K.S.U. Jayathissa¹, R. Mahendra³,
B.P.A. Jayaweera⁴, W.A.D.V. Weerathilake⁴ and D.M.S. Munasinghe¹

¹ *Faculty of Veterinary Medicine and Animal Science, University of Peradeniya*

² *Department of Animal Production and Health*

³ *Cargills Ceylon PLC*

⁴ *Faculty of Livestock, Fisheries and Nutrition, Wayamba University of Sri Lanka*

Corresponding Author: chanakarabel@vet.pdn.ac.lk

This study was conducted to identify the challenges private farms face that received Jersey-Friesian crossbred cattle imported from Australia and New Zealand and propose suitable mitigation/preventive strategies. Relevant data were collected from farm records, structured interviews, and on-farm observations of 11 randomly selected private dairy enterprises (from Central and North Western provinces) that received cattle from the 2015 and 2017 shipments. The major deficiencies identified in under-performing farms were (i) poor daily milk yields (as low as 4 L/day/cow), (ii) infertility, (iii) shrinking milking herd, (iv) poor body condition, (v) heat-stressed animals, (vi) limited pasture availability, (vii) limited pasture conservation practices, (viii) inconsistent availability and expensive pricing of concentrate feeds, (ix) optimal sub-usage of Total Mixed Ration, (x) delayed payments by milk collectors, (xi) limited extension/consultation services, (xii) sub-standard dairy management practices, and (xiii) limited prior „dairy experience“ of certain farm owners/entrepreneurs. The authors observed a vicious cycle among above factors where sub-standard feeding and management practices lead to poor body condition, poor milk production, infertility, and poor calving rates of cows resulting in poor daily milk collections and farm income from milk sales which hinders farmers' financial capacity of implementing proper feeding and management practices further aggravating infertility, body condition, and milk production of animals. Authors recommend the following strategies to avert a repeat of the same in future cattle importation programs: (i) adopt a transparent farmer selection process to identify experienced and motivated dairy farmers, (ii) import dairy breeds/crosses adaptable to tropical climates, (iii) implement routine monitoring mechanisms together with effective extension services, (iv) focus on hygienic milk production to get the highest possible farm-gate milk price, (v) use of sex-sorted semen or high-quality breeding bulls as appropriate, (vi) adopt recommended dairy management practices (esp. feeding, breeding, and heat-stress management), (vii) identify state-owned arable land and establish mechanisms for pasture cultivation, conservation, and delivery to farm-gate, and (viii) offer incentives (e.g. tax exemptions, concessionary interest rates) to encourage dairy farmers. If these „mitigation/preventive strategies can be realised, the concept of importing pregnant heifers with high-genetic potential can drive Sri Lanka towards achieving self-sufficiency in milk products.

Keywords: Dairy Cattle Importation Project, Dairy farming, Dairy management, Dairy research
Sri Lanka dairy farming

Provincial Level Power Delegation in Dairy Production and Animal Health; Strength or Failure?

K.K.N. Laknath*

Department of Animal Production and Health, Hambantota, Sri Lanka

**Corresponding Author: kknlaknath@yahoo.com*

The power vested to the Department of Animal Production and Health (DAPH) was delegated to the individual provinces and the APH sector has been trying to reach an average of its capacity since 1987. The objective of this study is to test the gap of provincial-level power delegation in DAPH. Preplanned, open-ended, 10 structured type questions related to administrative HRM, including grievances and suggestions to avoid such; focused on conducting formal and informal interviews and informal exit interviews with VSs and stakeholders. Convenient sampling was focused on testing the exclusion criteria of the study. According to the results, a key failure exposed is the inability of the livestock sector to reach a holistic approach due to power delegation. Different provincial strategies influence trust and bond between the public gradually. Government Veterinary Surgeons and other staff are facing difficulties such as lack of or zero buildings, transport facilities, lack of good quality drugs and continuous supply, distance from modern technology, zero testing capacities, lack of technical expertise in manpower and regional disturbances. Pertaining to regional disturbances, grievances get accumulated through the system, affecting health perspective and quality service. Around 84% of participants expressed that the major upcoming problem is attracting fewer veterinarians to DAPH. Poor regional protocols provide a negative impression for veterinarians, thus causing them to refrain from entering DAPH. Suggestions may vary based on root causes. Thus, centralised power should establish, intervene, implement strategies to monitor and govern animal health strategies without considering regional disturbances (One country One law) as per the empowerment of Animal Diseases act No.59 of 1992. Establishing, strengthening, and monitoring proper protocols for development projects, disease surveillance, remuneration policies and collection of service charges policies should be equal, scientific, and steady across the country. It is essential to upgrade the knowledge and talents of Government Veterinary Surgeons (GVS) through Continuous Professional Development (CPD) with experts from FVMAS; instead of considering regional disturbances. Implementation of methodological public awareness programs to express actual role and departmental capacity regarding “One Health approach” is essential. Though the main strength of the sector is GVS, it is doubtful that regional stakeholders and local administration have equally valued it. In light of difficulties and frustration, DAPH has empowered dedicated, talented GVSs to efficiently extend public service. Centralised power is a cornerstone of GVSs to receive recognition and work independently without regional disturbances and favouritism. Around 90% of participants believed that scientifically approaching disease diagnosis is a privilege. Thereafter, GVS’s offices need to be equipped with mini-labs and qualified lab assistants. Steps need to be taken to build Veterinary Hospitals in all districts under central DAPH governance. Policymakers need to create policies to restructure existing channels from DAPH to range level.

Keywords: Power delegation, DAPH, Favouritism

Molecular Characterization of Bacterial Isolates from Dairy Cows with Mastitis for Alternative Control Strategies

G.A. Gunawardana^{1*}, P.P. Jayasekara¹, G.A.D. Chandana², W.M.R.R. Wijethunga³, M.W.C.D. Palliyeguru² and R. Wimalagunaratne²

¹Veterinary Research Institute, Gannoruwa, Peradeniya, Sri Lanka

²Veterinary Investigation Centre, Nupe, Matara, Sri Lanka

³Business Management School, Galle Road, Colombo, Sri Lanka

*Corresponding Author: gnavavri@yahoo.com

Bovine mastitis is a major obstacle to increasing dairy productivity in Sri Lanka. Antimicrobials are largely used to treat mastitis. However, antimicrobial resistance and hazardous residues in milk result in urgent alternative control approaches. Though the focus on mastitis vaccination is rare in Sri Lanka, its usefulness is widely mentioned. Specific local vaccines are presently in need. Genetic level data on aetiological agents increase the opportunity to identify vaccine candidates. Therefore, the current investigation aims to molecular characterisation of bacteria for the initial selection of mastitis vaccine seeds. Out of 55 bacterial cultures collected during 2019-2020 from subclinical mastitis cases of different locations, DNA was extracted using a commercial kit (Promega, USA) from ten *Staphylococcus aureus* and five *Escherichia coli* originating from CMT strongly positive cows. PCR was performed to detect *tetA*, *blaSHV*, *sulI* and *catA1* genes involved in resistance to tetracycline, β -lactams, sulfonamide, and chloramphenicol correspondingly as per the published literature. Formerly published ISSR Primer „P02“ was used to perform Inter Simple Sequence Repeat PCR (ISSR PCR) to obtain DNA profiles which were analysed using ‘GelAnalyzer 2010’ and ‘PyElph’ software. All isolates possessed *sulI* genes whilst none carried *catA1* genes. One isolated from each bacterial species contained *tetA* gene. *blaSHV* gene was present in seven *S. aureus* and all *E. coli* isolates. Twelve isolates had more than one resistant genes. Variations in ISSR PCR band patterns of isolates were observed. No identical DNA arrays were found from both bacterial species, yielding 15 different fingerprinting profiles. In phylogenetic trees generated as per the single linkage clustering method, four main clusters of *S. aureus* were revealed, and seven isolates were in two closer clusters. Four *E. coli* isolates were arranged in two closer clusters compare to the fifth isolate. The link between resistance genes and ISSR profiles was partial. ISSR PCR generated distinct DNA profiles, disclosing different genotypes of the examined *S. aureus* and *E. coli* isolates. Similarly, phylogeny provided information on genetically close isolates and the divergences. In conclusion, detailed genetic classification by molecular methods can offer a new basis for mastitis vaccine seed selection. Further investigations are in progress.

Keywords: Bovine, Mastitis, ISSR PCR, Vaccines

Acknowledgement: This study was financially supported by the Department of Animal Production and Health, Peradeniya, Sri Lanka.

A Survey of Veterinarians' Attitudes and Perception toward Euthanasia of Companion Animals in Sri Lanka

S.A.C.H. Rodrigo¹, K.L.D.B.P. Liyanage², T.D.Nuwarapaksha², T. Paramanathan³ and D.D.N. De Silva^{4*}

¹*Department of Veterinary Pathobiology, Faculty of Veterinary Medicine and Animal Science, University of Peradeniya, Sri Lanka*

²*Department of Plantation Management, Faculty of Agriculture and Plantation Management, Wayamba University of Sri Lanka, Sri Lanka*

³*Department of Biochemistry, Faculty of Medicine, University of Jaffna, Sri Lanka*

⁴*Department of Veterinary Clinical Science, Faculty of Veterinary Medicine and Animal Science, University of Peradeniya, Sri Lanka*

*Corresponding Author: niranjlad@yahoo.com

Euthanasia is the act of deliberately ending an animal's life to relieve suffering. It is a controversial topic in the Sri Lankan context due to cultural and religious beliefs. This study was designed to investigate Sri Lankan veterinarians' attitude towards euthanasia of companion animals. A total of 185 veterinarians participated in completing an online questionnaire. Most veterinarians (51%) were companion animal practitioners who have 5-6 years of clinical practice (68%) and are employed in a clinic located in an urban area (62.9%). Veterinarians (88%) usually perform 1-2 euthanasia per month, administering only an overdose of general anaesthetic (65.1%). Many participants (68.9%) discuss with their colleague/s before deciding on euthanasia. Questions were included to assess the veterinarians' use of several communication and supportive practices to ease the stress of the client in the event of euthanasia. Commonly used communication practices by veterinarians to explore the clients' expectations regarding euthanasia included inquiring about client's emotional status (77.7%) and client's support network at home (41.3%). The support practices used in providing compassionate care to clients during euthanasia included showing empathy/ sympathy (61.3%), suggesting options for consolation (buying/adopting new pets) (39.8%), providing comfort items (a bottle of water, tissues, places to sit) (31.2%) and ensuring the client has recovered/follow up care (7.5%). The participants' years of experience was positively and significantly (Minitab 19, 95% CI level) associated with veterinarians' use of two communication practices (directly inquiring about client's emotional status- $p=0.002$ and client's support network at home- $p=0.038$) and two support practices (suggesting options for consolation - $p=0.002$, and follow up care- $p=0.03$). For many veterinarians (75%), two conditions were necessary to justify euthanasia; "the animals should be incurable and suffering" and "the owners should request to euthanize." In the absence of either condition, the veterinarians were inclined to refuse euthanasia. If owners requested further treatment for animals with serious medical conditions, 80.9% showed clear disapproval. On average, 97% showed clear disapproval of euthanizing healthy animals upon owners' request. These results indicate that owners' request takes precedence over the animals' condition for suffering animals, but not for healthy animals. This study revealed important facts regarding veterinarians' perception of euthanasia of companion animals. Many research questions still remain unanswered, such as owners' views of euthanasia and veterinarians' stress management. Future studies should be directed at elucidating these issues and seek a better way of managing companion animals' terminal care.

Keywords: Euthanasia, Companion Animals, Sri Lanka, Attitudes, Veterinarians

Non communicable disease status in zoo workers in Pinnawela with emphasis on elephant keepers

W.K.S.M. Weththewa¹, M.E.M. Liyanage², L.D.R.M. Bandaranayake², L.P. Malinga² and A. Dangolla¹

¹*Department of Veterinary Clinical Science, University of Peradeniya, Peradeniya,*

²*Open Zoological Garden, Pinnawela, National Zoological Garden, Dehiwela*

**Corresponding Author: adangolla@gmail.com*

A health clinic for employees of the Pinnawela zoological garden was held on 26th October 2018, to examine their Non Communicable Disease (NCD) status and to uplift positive working attitudes. This study was done with the permission of the relevant authorities. Three doctors, three nurses, two attendants and two health workers assisted in this clinic. With consent from individual participants, a questionnaire was administered. Definitions used by the Ministry of Health were used to decide on their respective health status. Random blood sugar, blood pressure, body weight, height and vision were checked in the participants. Those involved with elephant management (EM: n=22) and those not involved (Non EM: n=60) were compared using a Chi square test (5% significance). From 98 workers within the Pinnawela zoological garden, 82 participated and of them, 22 were from the EM group. Unsatisfactory Body Mass Index (BMI), blood pressure and random blood sugar was reported in 51% (42/82), (29%) 24/82, 1% (1/82) of the participants. Defective vision was reported in 10% (8/82). Analysis within the EM group using BMI indicated that six of them were either obese or overweight while only one was underweight. Four (4/22) had elevated systolic blood pressure and one had a defective vision. A total of five smoked while five regularly consumed alcohol. In the non-EM group, five were either obese or overweight, while 30 were underweight. Fourteen (14) non-EM workers had elevated systolic blood pressure and seven had vision problems. In addition, four of them smoked and nine regularly consumed alcohol. Significant levels of unacceptable BMI were found among the non-EM group who were overweight ($p<0.05$), and frequent smoking and alcohol consumption in the EM group ($p<0.05$) needs immediate attention. Looking at national levels on fasting blood sugar and issues of vision, the participants had fewer issues to report. Compared to privately owned elephant keepers, smoking and alcohol consumption was much less among the participants. Since most participants are from the Pinnawela village and surrounding areas, a general health clinic in the area must be conducted to examine whether the situation with regard to BMI, smoking and alcohol are the same and widely prevalent. Advice on diet, nutrition and regular physical exercise to participants can be recommended to uplift NCD status of workers.

Keywords: Non communicable diseases, Zoo workers, Elephant keepers

Acknowledgement: Director General, Dehiwela Zoological Garden, Director and Staff of Pinnawela Zoo, Doctors and medical staff participated in the health camp

The potency of animal anti-rabies vaccines marketed in Sri Lanka

H. Rathnadiwakara^{1*}, A. Servat², F. Cliquet², M. Wasniewski², J.C. Thibault³ and M. Gunatilake¹

¹*Dept. of Physiology, Faculty of Medicine, University of Colombo, Sri Lanka*

²*EU/OIE/WHO Reference Laboratory for Rabies, ANSES-Nancy, France*

³*Formerly of Boehringer Ingelheim, Lyon, France*

*Corresponding Author: hasanthirathnadiwakara.pdn@gmail.com

Anti-rabies vaccines (ARV) should be safe, effective with required potency for successful prevention of virus transmission. Sri Lanka is currently using seven brands of ARV for animals. At the time of planning this project and obtaining ethics approval in 2016, it was confirmed that there is no established procedure to test the potency of vaccines before registration by the Veterinary Drug Control Authority (VDCA). Therefore, the potency of the vaccines was assessed using a National Institutes of Health (NIH) test with ethics approval of the Faculty of Medicine, University of Colombo, Medical Research Institute, Colombo Sri Lanka and ANSES-Nancy laboratory France. This test was conducted in EU/OIE/WHO Reference Laboratory for Rabies, ANSES-Nancy, France. Seven single dose and one multi-dose preparations were blindly identified; A to H were tested for potency (Second multi-dose preparation sent for testing was not analyzed as the batch number of this preparation was similar to the single dose of the same vaccine brand which was tested). Four-serial five-fold dilution range; $10^{-0.3}$, 10^{-1} , $10^{-1.7}$, $10^{-2.4}$ of each test vaccine and reference vaccine were prepared in PBS (Phosphate-buffered saline). Twenty-one day old healthy female Swiss/OF1 mice (13g-15g), groups of 10 mice per each dilution, were used. Mice were injected intraperitoneally with 0.5ml of each dilution of the test vaccines and the reference vaccine. On the 14th day post-vaccination, mice were inoculated intra-cerebrally with a challenge dose of CVS (Challenge Virus Standard), providing about 50 LD₅₀ per 30µl. Mice were monitored daily for 14 days for signs of rabies. When the signs of trembling, shaky movements, convulsions were detected, animal was identified as rabies positive and euthanized. NIH potency test was based on „all or none“ response. Therefore, linear comparisons between the dose/ response (number of survivors) were developed for the reference vaccine and the test vaccines. Potency and confidence limits were calculated by comparing the ED₅₀ (median effective dose) of the reference vaccine to the ED₅₀ of the test vaccine. Based on the European Pharmacopoeia-8.0, inactivated rabies vaccines comply with mouse potency test if the estimated potency is ≥ 1 IU/ml in the smallest prescribed dose. Among tested vaccines, A, C, D, and E were compliant with NIH potency with potencies of 7.2 IU/dose, 12 IU/dose, 4.4 IU/dose and 3.4 IU/dose, respectively. Vaccine B (multi-dose preparation of brand A) had a potency of 1.3 IU/dose, even though the test did not meet the pre-determined validation criteria of NIH potency test. For the validation of this, tests must be repeated. The other three vaccines F, G, and H were not compliant with potency values < 1 IU/dose. The NIH test results showed that the assessment of the ARV potency is necessary before they are released to the market. Currently, we are conducting a study to determine the humoral immunity development conferred by these vaccines. Immunogenicity results could allow a comparison between potency testing and humoral response. As there are no established facilities to conduct NIH test for veterinary rabies vaccines in Sri Lanka, our aim is to look for the possibility of establishing a method to evaluate the relative potency of ARV based on their immunogenicity. Our plan is to submit recommendations based on the outcomes of this project which may help the authorities to select the best ARVs to be released to the Sri Lankan market. Since this is an ongoing study, we are not able to divulge the names of vaccines which do not have the required potency.

Keywords: Anti-rabies vaccines, NIH test, Rabies, Sri Lanka, Potency

Improving the Waste Management System of Medium Scale Dairy Operation to Control Odour Issue in Peri-urban Area: A Case Study

C.M. Namarathna^{1*}, S. Priyantha² and R.M.K.P. Rajanayake³

¹*Government Veterinary Surgeon's Office, Pallepola, Sri Lanka*

²*Livestock Planning and Economics Division, Department of Animal Production and Health, Sri Lanka*

³*Provincial Director's Office-Central Province, Department of Animal Production and Health, Sri Lanka*

**Corresponding Author: chathurinamarathna@gmail.com*

Generation of odour due to improper waste management negatively impacts dairy operations due to rapid urbanization and reduction of land availability. Medium-scale dairy producers are vital to fulfilling the demand for milk in the market. As a technical body, the Department of Animal Production and Health (DAPH) has been conveyed the advanced technologies to improve the productivity of available cattle resources, such as upgrading genetic potential, feeding management and housing management. However, with the enhancement of productivity and controlling the odour nuisance of the farm, waste management plays a significant role in ensuring sustainability of the operation, which gives positive feedback on dairy sector. In this case study, a medium scale dairy farmer in Pallepola Divisional Secretariat had an unpleasant experience of legal actions on the farm due to odour nuisance. However, the first complaint was made by a neighbor to Central Environment Authority (CEA) district office. A joint field inspection was organized by CEA and according to the decision made by the team who participated the inspection, the responsibility was given to Veterinary Surgeon's office for guidance. Low-cost remedies were used to improve waste management and thereby to control odour in order to obtain the Environment Protection License (EPL) from CEA; removal of existing biogas unit and slurry tank, the establishment of windbreak system, construction of 20m³ new bio gas unit with slurry tank and two soak pits, separation of solid waste daily, covered gutters, and integration of crop and azolla cultivation were practiced. The evaluation was dependent on the results of a questionnaire filled by attending members of the sniffing team at different time slots and places. Finally, the EPL (CE -302011RO) was obtained. Furthermore, lack of knowledge and low-profit margin are the main barriers that prevent them from adopting odour control solutions. However, considerable cogitation should be present in introducing advanced technologies and laboratory facilities, awareness programs of odour controlling, conducting researches are the important aspect that considered as next steps to assure the long-run sustainability of the livestock sector in the country.

Keywords: Waste management, Odor nuisance, Dairy

Antimicrobial resistance profiles in *Escherichia coli* isolated from an urban ecosystem in Sri Lanka: A one health approach

Y. Gunasekara¹, T. Nisansala¹, I. Wijewickrama¹, Y. Basnayake¹, S. Kottawatta¹, A. Silva-Fletcher² and R. Kalupahana^{1*}

¹*Department of Veterinary Public Health and Pharmacology, Faculty of Veterinary Medicine and Animal Science, University of Peradeniya, Sri Lanka*

²*Royal Veterinary College, University of London, UK*

*Corresponding Author: ruwanikalupahana@yahoo.com

Antimicrobial resistance (AMR) is a global health threat. In order to address this issue, it is crucial to take integrated actions across human, animal and environmental health sectors which imply “One Health”. Unlike farm animals, wild-animals are rarely treated with antimicrobials but, due to their extensive home range and feeding habits, we hypothesized that wild-animals act as a reservoir and transmission route of AMR within an ecosystem. Therefore, this study aimed to investigate the AMR profiles in *Escherichia coli* isolated from humans, animals (farm and wild) and environment (water) in an urban ecosystem in Sri Lanka. One square kilometre area from the urban ecosystem (Dompe) was selected to collect freshly voided animal faecal samples (85 farm animals and 64 wild animals) and 42 human faecal samples, and 40 water samples. Isolation and identification of *E. coli* were performed according to standard protocols. Susceptibility to 12 antimicrobials was tested according to CLSI (2019) guidelines. For frequency calculations, any *E. coli* isolates resistant against at least one antimicrobial was considered a resistant organism. The percentage of resistant *E. coli* in humans as well as in farm animals was 54%, while percentages were 47.7% and 45.9% in wild animals and water. From the total farm animals tested, poultry in Dompe showed the highest resistance levels. According to the isolates, wild-birds from Dompe had higher resistance than wild-mammals. Among all farm animal isolates in Dompe; the highest resistance was detected for Ampicillin (43%) followed by Tetracycline (40%), Nalidixic acid (30%) and Sulphamethoxazole (28%) whereas it was respectively 20%, 18%, 30% and 12% in humans isolates and 28%, 26%, 10%, and 10% in wild animals. Among isolates from water; highest resistance was detected for Ampicillin (20%) followed by Tetracycline (18%) and Streptomycin (10%). AMR in *E. coli* was observed for commonly used drugs in both farm animals and humans. Resistant isolates from water and wild animals suggest contamination of the environment. Thus, the findings of the present study which indicates the presence of resistant bacteria in all major components of the ecosystem iterates the need of a multi- sectoral One Health approach in combating the public health crisis related to AMR.

Keywords: Antimicrobial resistance, *E. coli*, One health, Urban ecosystem, Sri Lanka

Acknowledgement: Financial support rendered through UKRI Research England under the Bloomsbury SET Knowledge Exchange programme (grant no CCF-17-7779), Royal Veterinary College, University of London, UK

A Review of Laws Related to Animals and Veterinary Profession in Sri Lanka

H.C. Kannangara*

Ministry of Livestock, Farm Promotion and Dairy & Egg Related Industries

**Corresponding Author: chamarikannangara@yahoo.com*

The aim of this study is to identify legal documents related to animals and the veterinary profession in Sri Lanka and consequently identify gaps in the current context. All available legal documents (Acts, regulations, case studies and other written documents) were collected and studied comprehensively. During the study, dates of individual enactment of legislations and subsequent amendments were recorded and the time period of intervals of the amendments was noted. Case laws related to the respective legislations were collected and listed. It was observed that the very first legal document was enacted in 18th Century, and was more than 130 years old. Rabies was the first disease identified as the most important animal disease to be controlled by imposing laws. During the past 130 years, only a few enactments were enacted in the country and many of those were not had been timely amended for the benefit of animals and the veterinary profession. The absence of regulations for most of the ordinances and acts have created issues in implementing the law. It was observed that although several amendments have been made to some of the legislations, the punishments for the law breakers have not been adequately increased according to the present requirements. In a few of the legislations, the punishments imposed at the time of enactment remain the same until now. However, when compared with other South Asian countries, Sri Lanka has introduced various laws to safeguard animals. On perusal of the above, it is important to amend the laws and regulations according to the present requirements and introduce new laws and regulations to safeguard animal welfare and uplift the veterinary profession based on international laws and standards.

Keywords: Animal Laws, Veterinary legislations, Ordinances, Acts

Investigation of Antimicrobial Resistance in *Escherichia coli* Isolated from Wild Animals at Hambegamuwa: Sri Lanka

B.M.Y.I. Basnayake¹, G.G.T. Nisansala¹, P.I.J.B. Wijewickrama¹, U.S. Weerathunga¹, N.K. Jayasekera², A.W. Kalupahana³, R.S. Kalupahana¹, A. Silva- Fletcher⁴ and K.S.A. Kottawatta^{1*}

¹*Department of Veterinary Public Health and Pharmacology, Faculty of Veterinary Medicine and Animal Science, University of Peradeniya*

²*Department of Veterinary Basic Sciences, Faculty of Veterinary Medicine and Animal Science, University of Peradeniya*

³*Department of Veterinary Pathobiology, Faculty of Veterinary Medicine and Animal Science, University of Peradeniya, Sri Lanka*

⁴*Royal Veterinary College, University of London, UK*

*Corresponding Author: sarunika@yahoo.com

Antimicrobial resistance (AMR) is a global concern in animal and human health. There has been increasing interest in AMR in wild animals as they act as indicators of resistant bacterial spread through the environment. The objective of the study was to investigate the AMR profiles of wild animals in a rural ecosystem in the country: Hambegamuwa. One square Km area at Hambegamuwa was mapped using GPS as the sampling area. The study was conducted for a period of four months from November 2020. Voided faecal samples were collected from 130 wild animals, including 62 mammals, 40 birds and 28 reptiles (land monitors only). *Escherichia coli* (*E. coli*) was isolated using published standard methods and AMR profiles were investigated for 12 antimicrobials using disk diffusion method following CLSI guidelines. Seventy-two percent (45/62) of mammals, 65% (26/40) of birds and 71% (20/28) reptiles were positive for *E. coli*. Maximum of two *E. coli* from each sample to a total of 157 were tested for AMR of which 79, 47 and 31 were from mammals, birds and reptiles respectively. *E. coli* from mammals reflected the highest resistance (11.3%) for Streptomycin followed by Ampicillin (10%). The highest resistance in *E. coli* from birds (12.7%) and reptiles (22.5%) was for Ampicillin. Both birds and reptiles had resistant isolates against Streptomycin, Tetracycline, nalidixic acid and 5 mammals, 2 birds and 2 reptiles were detected with cefotaxime resistant *E. coli* isolates. Out of 157 isolates, the resistance for Ampicillin, Streptomycin, nalidixic acid, cefotaxime, and Tetracycline were 13.3%, 10.8%, 7%, 6.3%, 5.7%, respectively and 100% susceptibility was not observed for any of the antimicrobials tested. Statistical analysis to detect the difference in AMR levels between mammals, birds and reptiles for each antimicrobial revealed no statistically significant difference. Nine multi-drug resistant isolates were identified from spotted dove, domestic pigeon, land monitor and elephant. The incidence of AMR in wild animals even in a less contaminated rural ecosystem reflects the importance of future studies on AMR in diverse ecosystems, including livestock, wildlife and environment, to combat the issue of AMR.

Keywords: Antimicrobial Resistance, *E. coli*, Rural Ecosystem, Wild animals, Mammals, Birds, Reptiles

Acknowledgement: Financial support rendered through UKRI Research England under the Bloomsbury SET Knowledge Exchange Programme (grant no CCF-17-7779), Royal Veterinary College, University of London, UK

***mecA* gene based characterization and antimicrobial resistance of *Staphylococcus spp* recovered from commercial eggs collected from layer farms in Kurunegala District**

H.C. Gallage¹, H.M.T.K. Karunaratna¹, W.A.S.M. Premaratne²
R.S. Kalupahana¹ and K.S.A. Kottawatta^{1*}

¹*Department of Veterinary Public Health and Pharmacology, Faculty of Veterinary Medicine and Animal Science, University of Peradeniya, Peradeniya*

²*National Livestock Development Board, Sri Lanka*

*Corresponding Author: sarunika@yahoo.com / sandavphp@gmail.com

Methicillin-resistant *Staphylococcus aureus* (MRSA) is one of the epidemiologically fittest modern bacterial pathogens that can cause serious impacts on public health. *mecA* gene is the main genetic element responsible for methicillin resistance. Animal originated food is a known potential source for *Staphylococcus aureus* (SA) and MRSA. Previous findings from our laboratory shows, around 50% of *mecA* gene pool among *Staphylococcus spp* isolated from commercial layer chickens. This study aimed to isolate *Staphylococcus spp* from commercial eggs and characterize the isolates based on the *mecA* gene. Eggs were collected from fourteen semi-intensive medium scale chicken layer farms in Kurunegala district. From each farm, five eggs were collected and pooled during testing. Egg shell washings, white and yolk were collected following published protocols, and tested to identify staphylococci and SA using mannitol salt agar and biochemical reactions including DNase test. Genotypic characterization was done by detecting *mecA* gene using PCR and antimicrobial resistant profiles of identified staphylococci isolates were detected for six antimicrobials following CLSI, 2013 guidelines. *Staphylococcus spp* were recovered from all (100%) egg shell washings and from 13 (92.85%) egg white and egg yolk samples separately. Among those 40 staphylococci, 14 were SA and others were recorded as *Staphylococcus spp*. Furthermore, nine (9/14), five (5/13) and three (3/13) isolates from egg shells, white and yolk, respectively harboured *mecA* gene reporting 42.5% (17/40) of *mecA* gene prevalence. The above results revealed that 25% (10/40) of the isolates were MRSA. Four (4/40=10%) methicillin susceptible SA (MSSA), seven (7/40=17.5%) methicillin resistant *Staphylococcus spp* (MRS) and nineteen (19/40=47.5%) methicillin susceptible *Staphylococcus spp* (MSS) were detected. All staphylococci were susceptible to gentamicin. The highest resistance (40%) was recorded for erythromycin. Except three MRSA, other MRSA, MRS, MSSA and MSS were susceptible to ceftiofur: surrogate for *mecA* mediated oxacillin resistance as per CLSI. Our study shows the presence of *S. aureus*, MRSA and MRS in commercial eggs highlighting the possibility of food chain contamination. Even though the majority of MRSA and MRS isolates were susceptible to ceftiofur, they were *mecA* gene carriers. This is noteworthy that silence expression of the high rate of resistant gene poses a potential risk for horizontal gene transfer.

Keywords: *mecA* gene, Methicillin-Resistant *Staphylococcus aureus* (MRSA), Foodborne Pathogen

Importation of antimicrobials intended for veterinary use and related regulatory measures in Sri Lanka during 2016-2020

U. Sinhalagoda¹, M.D.N.Jayaweera¹, C. G. Wijesinghe¹, S. Seneviratne¹ and J. Priyangika¹

¹*Veterinary Drug Control Authority, Department of Animal Production and Health*

*Corresponding Author: mdnjayaweera@yahoo.com

Antimicrobial Resistance (AMR) is one of the most serious global public health threats in this century. This study analysed the data on import of antimicrobial agents intended to be used in animals 2016-2020 recorded at the Veterinary Drug Control Authority, Department of Animal Production and Health (VDCA/DAPH). The objective of the study was to identify the fluctuations of AMU (Antimicrobial Usage) 2016-2020 and the main reasons for these fluctuations. The data was collected from the submitted annual AMU reports to OIE (World Organization for Animal Health) by the Registrar/VDCA and veterinary epidemiological bulletins between 2016-2020. The data shows the import of antimicrobials mainly for therapeutic purposes. In 2016 the quantity of AGPs (Antibiotic Growth Promoters) imported was (55.85 MT) even higher than that of therapeutic antimicrobials (36.09MT). As a consequence of restrictions imposed on the import of AGPs in 2017, it has been reduced to merely 360 kg. There were 152 antimicrobials containing Veterinary Medicinal Products (VMPs), imported by 28 importing companies at the end of 2020. Annual import quantities of active ingredients varied from 40MT (2018) to 92MT (2016) during this period. The total amount of active ingredients imported during the period was 343.70MT, Macrolides being the highest (78.96MT) and Cephalosporins being the lowest (33.80MT). Tylosin was the main contributor in the Macrolide class and the highest use was noted in 2019 (42.6MT). This could be due to the increased prevalence of Chronic Respiratory Disease (CRD) in poultry in the country. Increased quantities of Penicillin in 2019 (16.9MT) and 2020 (18.8) can be due to the usage of injectable Penicillin to prevent secondary infections of Foot and Mouth Disease (FMD) and Lumpy skin Disease outbreaks in 2019-2020. The remarkable increase in the amount of Sulphonamide used in 2017(320.4MT) compared to other years could be attributed to the high prevalence of *Salmonella pullorum* and Coccidiosis outbreaks in poultry. In 2017 some favourable decisions were taken by the VDCA/DAPH to control the bulk use of therapeutic antimicrobials for prophylaxis. Maximum pack sizes for imported antimicrobial were limited to 1Kg and 1L and it was made mandatory for the importers to submit data of the marketing information of antimicrobials to the VDCA/DAPH as an initial step to monitor antimicrobial distribution and usage patterns. The antimicrobial distribution report is randomly checked for verification and considered a prerequisite for the pre-clearance recommendation issued by the VDCA/DAPH for the import of a subsequent consignment of a particular antimicrobial product. Registrations of VMPs containing Streptomycin, Colistin and 3rd generation Cephalosporins were also discontinued by the VDCA. This article would be useful for all practicing veterinarians in the country, employees of the veterinary pharmaceutical industry, animal feed industry, veterinary students, different sectors such as livestock, poultry, companion animals and aquaculture to progress through their careers with a minimum contribution towards AMR in Sri Lanka.

Keywords: Antimicrobial Resistance, Veterinary Drug Control Authority Antibiotic Growth Promoters

Cutaneous Plasmacytoma on a Foot Pad of a dog: A case report

I.N. Kumaravithana^{1*}, H.M.S. Wijekoon² and H. Ariyaratna²

¹*Veterinary Investigation Centre, Badulla* ²*Department of Veterinary Clinical Sciences*

²*Faculty of Veterinary Medicine & Animal Science, University of Peradeniya*

*Corresponding Author: isuriniluka@yahoo.com

Cutaneous plasmacytoma is one of the round cell neoplasms often reported in middle-aged to old dogs. Although the skin of the digits is reported as a common site for cutaneous plasmacytomas, foot pad lesions are not reported in dogs in Sri Lanka. This article describes a plasmacytoma that occurred on a foot pad of an eight-year-old, male Labrador retriever presented for limping of the right forelimb for several weeks. General clinical examination revealed a moderately circumscribed, erythematous, and ulcerated mass approximately of 1 cm diameter, mildly protruding over the foot pad of the right front paw. The fine-needle aspiration biopsy obtained from the lesion revealed a highly pleomorphic population of round cells with eccentric nuclei and basophilic cytoplasm. Anisocytosis and anisokaryosis of the cell population were high with occasional binucleated and multi-nucleated cells. Occasionally, the nuclei were indented and there were signet ring shape cells. The lesion was tentatively diagnosed as a round cell tumour while the differential diagnoses included cutaneous plasmacytoma, atypical lymphoma and histiocytoma. The lesion was surgically excised under local anaesthesia and the resected mass was sent for histopathology. Microscopically the mass was poorly demarcated and composed of nests and bundles of round cells streaming between moderately thick collagenous and fibrovascular stroma. The neoplastic cells were round to ovoid and nuclei are often eccentrically located. The cytoplasm was centrally brightly eosinophilic and transparent while the periphery of the cytoplasm was often basophilic. Frequently the nuclei were sickle shaped or indented. Binucleation and multinucleation were common. Some cells contained large prominent single or multiple nucleoli. The cellular and nuclear pleomorphism were high. Occasionally the neoplastic cells had peri-nuclear halo similar to mature plasma cells. Mitotic rate was < 1 per ten, 40 x high power fields. The histopathology findings were mostly consistent with a cutaneous plasmacytoma. The dog was completely cured after the surgery and tumour recurrence was not reported in the five months follow up. The findings of this case suggest that although uncommon, cutaneous plasmacytomas need to be considered a differential for mass forming lesions on foot pads in dogs.

Keywords: Foot pad lesions, Dogs in Sri Lanka, Round cell neoplasms

Clinico-Pathological Diversity of Canine Oral Cavity Tumors: A Retrospective Study

S.A.C.H. Rodrigo, P.G.A.S. Palkumbura, W. Jayaweera, G.S.P. de S. Gunawardena and
R.R.M.K.K. Wijesundera*

Department of Veterinary Pathobiology, Faculty of Veterinary Medicine and Animal Science,
University of Peradeniya

**Corresponding Author: kavindra77@gmail.com*

Thorough knowledge on Oral Cavity Tumors (OCTs) of dogs is essential for veterinarians because of its commonality among dogs in Sri Lanka. However, the diversity of canine OCTs in Sri Lanka is largely unknown, which impedes effective early diagnosis and proper treatment approach of the condition. The primary objective of this study was to evaluate the demographic data and clinico-pathological features of OCTs in dogs in Sri Lanka. This study was performed by collecting the data of biopsy reports of thirty (n=30) OCTs received by the histopathology laboratory of the Department of Veterinary Pathobiology, Faculty of Veterinary Medicine and Animal Science, over a two-year period (2018 to 2020). The age, breed, sex, clinical signs, location, gross and histopathology of OCTs were analyzed. Inflammatory and hyperplastic conditions, which commonly occur in canine oral cavity were not included in the study. A higher predominance of male subjects (n=20, 66.6%) and mixed breed dogs (n=18, 60%) was identified. The most commonly affected pure breed was the German Shepherd (n=5, 16.6%). The mean age of OCTs diagnosis was 7.1 ± 4.1 years. The common clinical signs of OCTs, included facial swelling (72%), hypersalivation (68%) and bloody oral discharge (51%). Common locations of tumors were gingiva, buccal mucosa, salivary glands, tongue, palate and lips. Of these, gingiva (n=16, 24.4%) is the most commonly affected site. The majority of tumors (n=13, 43.3%) belonged to 2-4 cm category (T2) which was classified following the World Health Organization guidelines. Regardless of the type, the tumors were irregularly shaped (54%), bleeding/ulcerated surfaced (62%) and showed a broad attachment to the point of origin (51%). High histological diversity in OCTs of dogs was observed. A higher proportion of tumors were histologically malignant (n=16, 53.3%). The most common malignant tumor was the melanoma (n=8, 26.6%) followed by squamous cell carcinoma (n=4, 13.3%) and fibro sarcoma (n=2, 6.6%). Of 14 benign tumors, fifty percent (50%) were odontogenic of origin while peripheral odontogenic fibroma (n=4) predominated. Overall, these findings emphasize the necessity of improving awareness on OCTs among veterinarians. OCTs often remain unidentified as the oral cavity is not regularly checked by the owner. Therefore, owners must be vigilant about the occurrence of the above clinical signs and gross features so early identification can be done as this report necessitates the thorough investigation of canine OCTs in Sri Lanka. Further studies must be conducted to research the effects of sex, age, and breed predisposition on the occurrence of OCTs.

Keywords: Oral Cavity Tumors, Dogs in Sri Lanka, Histopathology

An aberrant movement of a gunshot pellet in a dog: A case report

P.G.A.S. Palkumbura, S.A.C.H. Rodrigo, R.M.T.M. Ramanayake, G.S.P. de S. Gunawardena
and R.R.M.K.K. Wijesundera*

Department of Veterinary Pathobiology, Faculty of Veterinary Medicine and Animal Science, University of Peradeniya

*Corresponding Author: kavindra77@gmail.com

Recently, companion-animal death due to gunshot wounds has seen increased public concern in Sri Lanka. Gunshot injuries are projectile or penetrating injuries and could be fatal without immediate medical care. This report discusses the unusual case of a gunshot death of a dog. Tumu, a 3-year-old crossbred, male dog, was shot by an air rifle and pursued immediate veterinary care. However, the patient had lost a significant amount of blood and had died after 30 minutes, before any medical intervention was done. A detailed postmortem examination was requested on legal aspects. During the external examination, pale mucosa, and dried blood on the coat of the right-thoracic region were observed. In the area cranial to the right-elbow joint, a focal well-demarcated (approx. five mm-in diameter) hole was detected, which could be considered as the entrance wound of the pellet. Interestingly, no exit wound was detected. There were locally extensive bruises in the right-biceps and the right-pectoral muscles. The pellet had severed the right-jugular vein resulting the haemorrhage and haemothorax (approx. 100 ml). A focal well-demarcated piercing wound was detected on the third-intercostal muscle. There was a well-demarcated wound on the right side of the membranous part of the diaphragm. No abnormalities were detected in the heart and lung. A liver rupture was observed in the diaphragmatic surface of the right-lateral lobe. A metal pellet (4.5 mm in diameter) was found entrapped in the mesenteries. Gross findings are suggestive that the pellet had entered from the right-thoracic region and trajectory penetrated through the right-jugular vein, right-biceps, and right-pectoral muscle and entered the thoracic cavity via third intercostal muscle. Surprisingly, without causing any damage to the thoracic organs, the pellet had entered the abdomen, perforating the diaphragm forming a direct communication between thoracic and abdominal cavities. Afterwards, the pellet had gone into the liver causing liver rupture and had finally gotten trapped in the mesenteries. Postmortem findings suggest that the cause of death of the animal could be due to hypovolemia and resultant multi-organ failure. Aberrant movement of the pellet would give valuable insights to veterinarians when attending gunshot wounds in the future.

Keywords: Gunshot, Aberrant movement, Gunshot wounds

Transmissible Venereal Tumor in a 4-month-old Puppy: A case report

K.L.A. Ishara^{1*}, H. Ariyaratna² and E.M.K.A.Thilakarathne²

¹*Animal SOS Lanka (pvt) Ltd*

²*Department of Veterinary Clinical Sciences, Faculty of Veterinary Medicine & Animal Science, University of Peradeniya*

*Corresponding Author: achini.ishara@gmail.com

Canine Transmissible Venereal Tumor (CTVT) is the only contagious tumor reported in dogs. Generally, CTVT is transmitted through coitus. Therefore, the disease is mostly reported in sexually intact dogs, and is extremely rare in puppies. This report describes a CTVT diagnosed in a sexually immature 4 month old female puppy. The puppy was a rescue received by an animal shelter. During the initial general clinical examination, a lobulated, none ulcerated cutaneous mass, approximately of 2 cm x 2.5 cm in size was identified caudal to the right commissure of the oral cavity. The mass did not elicit pain on palpation and was firm in consistency. The differential diagnoses considered were excessive granulation tissue formation secondary to a traumatic injury, foreign body granuloma and insect bite reaction. The puppy was treated with cephalexin (20mg/kg) and meloxicam (0.1mg/kg). Despite treatments, the mass kept growing and therefore, the mass was surgically excised under general anesthesia and sent for histopathology to obtain a definitive diagnosis. Microscopically, the mass was composed of packets and sheets of round cells separated by a fine fibrovascular stroma. The neoplastic cells had distinct cytoplasmic borders, a moderate amount of lightly basophilic cytoplasm with fine vacuolation at the periphery of the cytoplasm. The nuclei were round, mostly eccentric and contained coarsely stippled chromatin. Often, nuclei contained single, prominent nucleoli. The mitotic rate was 3 per 10 high power fields. Throughout the neoplasm, there were multi-focal aggregates of small lymphocytes. These microscopic features were mostly consistent with CTVT. The surgical margins were clean and complete. Due to the sexual immaturity and very young age of the puppy, further investigations were carried out to identify the source of CTVT. The investigations revealed that the puppy was nursed by a foster lactating bitch with a vaginal CTVT. It is possible that the tumor cell transplantation would have occurred through licking related close interaction with the affected bitch. The surgery was performed on March 2021 and no recurrence was observed until present. This is the first report of CTVT in a sexually immature puppy in Sri Lanka to the Author's knowledge.

Keywords: Canine Transmissible Venereal Tumor, Sexually immature, Surgical excision

Intestinal Lipogranulomatous Lymphangitis in a German Shepherd dog: A case report

G.A.D.K.K. Gunathilaka, H.D.S. Hewapathirana, S. Kabilan, M.G.T.M. Prasadinie, T.M.S.K. Piyadasa, D.D.N de Silva and H. Ariyaratna*

Department of Veterinary Clinical Sciences, Faculty of Veterinary Medicine and Animal Science, University of Peradeniya

*Corresponding Author: hsariyaratna@pdn.ac.lk

Lipogranulomatous lymphangitis is a rare inflammatory disease of the intestinal lymphatic vessels and surrounding tissues caused by a chronic leakage of lipid-rich chyle. This report describes a case of multi-focal intestinal lipogranulomatous lymphangitis (ILL) in a one-year-old, female German shepherd presented to the Veterinary Teaching Hospital of the University of Peradeniya. The presenting complaints of the dog were dyschezia, hematochezia and tenesmus for two weeks. During the rectal examination, the dog showed signs of pain. Firm, variably sized nodules were palpated at the level of the pelvic floor. The rectal nodules were tentatively diagnosed as inflammatory polyps, while intestinal neoplasia was considered less likely due to the young age of the patient. The treatments included prednisolone (0.5 mg/kg bid for 2 weeks) to reduce inflammation and laxative (Cremofin®, 2 tsp bid) to relieve constipation. During the follow-up in two weeks, clinical examination findings were similar, except for the absence of hematochezia. Due to the lack of response to treatments, it was decided to surgically excise the rectal nodules. During the surgery, it was observed that the nodules are not localized to the rectum but scattered multi-focally along the serosa of the rectum, large intestine and small intestine. It was only possible to remove a few nodules, due to their extensive distribution. Histopathology of the nodules included variably sized, granulomas spanning the submucosa, muscularis mucosa and serosa of the rectum and large intestine. The granulomas were irregular and consisted of central amorphous, fibrillar, basophilic material, surrounded by foamy macrophages and multinucleated giant cells. Some granulomas had an adjacent associated lymphocyte aggregate. The submucosal lymphatics were distended and there were large, thick-walled lymphatics surrounded by granulomas or lymphoid nodules in the submucosa. In addition, there was an extensive transmural inflammatory cell infiltrate composed of lymphocytes, plasma cells and neutrophils. These findings were consistent with ILL. The dog died three weeks after the surgery, possibly due to the complications caused by the extensive intestinal lesions observed during the operation. The case suggests the consideration of ILL as a possible differential diagnosis for dogs with intestinal mass lesions.

Keywords: Intestinal lipogranulomatous lymphangitis, Inflammatory polyps, Neoplasia

Management of Fractures in Ruminants in a field setting using External Coaptation

E.M.U. Dissanayake*

Government Veterinary Surgeon's Office, Mawanella, Sri Lanka

**Corresponding Author: udenivetdissanayake@gmail.com*

Limb fractures are common in cattle and goats to maintain under certain management systems. External Coaptation is a versatile method for rigid immobilization of long bone fractures in ruminants along with a cast. This abstract describes four (4) cases reports of management of fractures in cattle and goats in field settings using External Coaptation with casts. External Coaptation can be used as the primary method of fracture fixation or in an aid to enhance the stability provided by another primary fixation modality. It can be used in different clinical scenarios, including simple fractures, open or compound fractures, and highly comminuted fractures in farm animals, as the cost is lower and can be handled in a field setting. Two cows and two goats were involved in the study. Case 1 (2yrs, Bovine Jersey heifer of 350kg) had a closed complete fracture of right side femur just above the patella, Case 2 (4yrs, Bovine, Jersey x Friesian bred cow of 400kg) and Case 3 (2yrs, Caprine Jamnapari female, 35kg) both had closed, complete fracture of tibia and fibula in left limb, Case 4 (1yr, Caprine, Jamnapari female of 25kg) had a closed complete fracture of ulna and radius in the left limb. In all four cases, the wooden splint was used to provide external coaptation for temporary stabilising the fracture (4 wooden planks were placed around the fracture at a 90 degrees angle, parallel to the bone, on caudal cranial, medial and lateral aspects of the limb). A padded bandage was applied to position the splints. All wooden planks were extended to the ground (to a level immediately distal to the sole of the hooves). Plaster of Paris (POP) was applied over it. All treated animals were able to place their fixed limbs slightly on the ground from the first 2 days after the cast was applied. Cast and splints were removed after 21 days in all 4 cases. All the animals clinically improved gradually and showed satisfactory alignment of their limbs and were able to bear weight without limping after two weeks. Based on our experience, external coaptation and application of POP casts can be considered a cheap, safe, and successful treatment method for repairing and managing long bone fractures in cattle and goats under local farming conditions.

Keywords: External coaptation, Splint, Plaster of Paris, Limb fracture

Multilobular tumour of bone in a dog: A case report

K.A.R.K. Perera*, S. Kabilan and H. Ariyaratna

Department of Veterinary Clinical Sciences, Faculty of Veterinary Medicine & Animal Science, University of Peradeniya

**Corresponding Author: rkperera27@gmail.com*

Multilobular tumour of bone (MTB) is an uncommon bone tumour in dogs that frequently occurs on the skull. These tumours develop slowly, are locally invasive, and have the potential to compress and invade the surrounding tissues. Despite the slow growth rate of these tumours, the prognosis of many reported MTBs is poor. This article describes an MTB diagnosed by cytology in a 7-year-old Rhodesian Ridgeback dog brought into the Veterinary Teaching Hospital Peradeniya for treatment, with a history of progressive, painless growth over the frontal area of the cranium. The skull radiographs showed a mass lesion with mixed radiopaque and radiolucent areas consistent with the “popcorn ball” appearance described for MTBs. The adjacent bones did not show osteolysis. Fine needle aspiration biopsy obtained from the lesion revealed an atypical population of mesenchymal cells admixed with pink matrix material suggestive of osteoid produced by neoplastic cells. The mesenchymal cells had large, mostly eccentric nuclei with prominent single or multiple nucleoli. The cytoplasmic borders of the cells were indistinct, and the cytoplasm was variably basophilic. The anisocytosis and anisokaryosis of the mesenchymal cells were high. The number of inflammatory cells in the background was minimal and not suggestive of concurrent inflammation. The differentials included osteosarcoma, chondrosarcoma and MTB. The location, radiological appearance and cytological findings together were strongly suggestive of an MTB than other tumours of the bone. The owner did not consent for a biopsy for histopathology. Surgical tumour excision with wide margins is the recommended treatment for MTBs while adjuvant chemotherapy with Doxorubicin or Cisplatin has been reported to be of variable usefulness. The owner did not consent for surgery and opt for chemotherapy with Doxorubicin (30 mg/m²). Doxorubicin was selected considering the less severe side effects compared to those of Cisplatin. The dog showed mild improvement after the first two doses of Doxorubicin. However, chemotherapy had to be stopped later due to other concurrent disease conditions and the dog died after 3 months of diagnosis.

Keywords: Multilobular tumor of bone, Metastasis, Bag of popcorn, Mesenchymal cells, Doxorubicin

Mandibular Fracture Correction Using Dynamic Compression Plates in a Dog

S. Kabilan*, R.M.N.S. Nuwanshika, G.A.D.K.K. Gunathilaka, H.D.S. Hewapathirana,
T.M.S.K. Piyadasa, H.M.S. Wijekoon and D.D.N de Silva

*Department of Veterinary Clinical Sciences, Faculty of Veterinary Medicine and Animal Science,
University of Peradeniya*

**Corresponding Author: kabi1040@gmail.com*

Fractures of the mandible can occur due to various reasons, including trauma, pathology of bone, pathologic fracture secondary to periodontal disease, and iatrogenic. Surgical intervention is necessary to establish normal occlusion and normal mandibular function. This case report describes a successful treatment of a fracture using dynamic compression plates without any complications. A 1.5-year-old, female intact Rhodesian Ridgeback weighing 32 kg was presented to the Veterinary Teaching Hospital (VTH), the University of Peradeniya, with a fractured mandible due to a road traffic accident. The fracture was described according to observation and per radiographs as a simple, open, transverse fracture located distal to the right mandibular canine tooth (404). All the teeth were intact and no fractured teeth were detected at the time of presentation. The dog was prepared for immediate surgical intervention. An incision was made ventral to the gingival surface over the alveolar mucosa to form a pocket-like space. A 2.7mm DCP with 2+2 holes combining with 2.7mm self-tapping screws were selected to span the fracture gap. The plate was placed on the vestibular surface of the jaw and two screws each were inserted in either side of the fracture. Routine closure of the incision was done using absorbable suture material. Ten days after the surgery, complete osseointegration and bone healing were achieved, allowing for a complete return to normal occlusion and function. This case report describes the importance of using a fixation method for mandibular fractures in dogs, which is a common problem untreated or treated with alternative methods in Sri Lanka. Dynamic compression plates gave rigid fixation, maintained maximum immobilisation and enabled eating within two days. Because of their small size, surgical trauma and peripheral soft tissue injuries were minimised. The microplate fixation system was shown to be adaptive to the fracture line, flexible, and simple to use in this study. Therefore, the same could be recommended to restore rapid functionality.

Keywords: Mandibular fracture, Compression plates, Fixation

Uncommon presentations of a common disease: Two cases of Transmissible Venereal Tumour

K.A.R.K. Perera*, I.P.C.S. Kithsiri, C. Abeykoon and H. Ariyaratna

Department of Veterinary Clinical Sciences, Faculty of Veterinary Medicine & Animal Science, University of Peradeniya

**Corresponding Author: rkperera27@gmail.com*

Transmissible venereal tumour (TVT) is a common neoplasm frequently found among sexually intact dogs. Of all canine neoplasms, TVT is the only neoplasm known to exhibit a contagious behaviour where transmission between dogs mainly occurs through coitus. Transmissible venereal tumours are generally present on external genitals and cytology of TVT is characteristic. Therefore, diagnosis of TVT is often straightforward and not challenging. This article describes two TVT cases diagnosed and treated at the Veterinary Teaching Hospital, Faculty of Veterinary Medicine and Animal Science of which the lesions were absent in external genitals. The first case was a one-year-old, intact-male, Golden Retriever presented for difficulty in breathing, epistaxis, and multiple, variably sized, pale-tan, firm to fragile conjunctival and cutaneous nodules. Samples were collected for cytology from conjunctival and cutaneous lesions and nasal cavity. All cytological preparations revealed a population of round cells that had cytological features consistent with TVT including eccentric nuclei, lightly basophilic cytoplasm and punctate vacuoles arranged along the periphery of the cytoplasm. As the owner mentioned that the dog is completely in-house, further inquiries were made to identify the source of TVT. This revealed that there is another dog at the same premises which is not completely in-house and showing dribbling of blood from external genitals for several months. The dog was treated with vincristine sulfate (0.5mg/m²) and the owner was asked to bring the other dog for treatment. The second case was a five-year-old, intact-male dog presented for a unilateral facial swelling around the nasal area and difficulty in breathing for several months. The skin over the facial swelling had a scar tissue suggestive of a dog bite. Cytology of the samples collected from the facial swelling by fine needle aspiration revealed a round cell population consistent with TVT. The two cases described here lacked genital lesions characteristic of TVT and therefore diagnosis was challenging than typical TVT cases. These findings suggest the necessity of including TVT as a differential for dogs presenting with breathing difficulties related to upper respiratory tract, epistaxis, or cutaneous nodules even in the absence of characteristic genital lesions.

Keywords: Transmissible venereal tumour, Vincristine sulfate, Basophilic cytoplasm, Genital lesions

Combination of Surgical Correction and Platelet-rich plasma therapy for Achilles tendon rupture: Two successful clinical cases

H.D.S. Hewapathirana*, G.A.D.K.K. Gunathilaka, S. Kabilan, K.A.R.K. Perera, M.G.T.M. Prasadinie, T.M.S.K. Piyadasa, H.M.S. Wijekoon and D.D.N de Silva

Department of Veterinary Clinical Sciences, Faculty of Veterinary Medicine and Animal Science, University of Peradeniya

*Corresponding Author: ghanushkahew@yahoo.com

Achilles tendon rupture is a common traumatic injury encountered in dogs. Evaluation and diagnosis of the severity of the condition are critical in deciding the method of surgical correction. The post-operative healing of the ruptured tendon poses a challenge due to low vascularisation of the tendon and adhesions with surrounding tissue which restricts active and passive movements. With the advancement of regenerative medicine, many studies have shown successful healing of tendon injury with the use of Platelet Rich Plasma (PRP) in human medicine though there is a dearth of literature related to veterinary medicine. This study evaluated the effect of PRP treatment in enhancing the healing of ruptured Achilles tendons after surgical correction. Two cases of Achilles tendon rupture were presented to the Veterinary Teaching Hospital. One is a 7-year-old, male Great Dane (patient 1) and the other a 5-year-old female Belgium Shepherd (patient 2) were with a complaint of non-weight bearing lameness and a wound above the hock joint. The physical examination revealed traumatic injury involving the skin, subcutaneous tissue and completely severed Achilles tendon with a severe loss of tendon structure resulted in lameness of the affected limb. Lateral radiographical view indicated disintegration of the Achilles tendon. The surgical intervention involved termino-terminal loop suture tenorrhaphy using non-absorbable sutures. For patient 1, 1 ml of autologous PRP solution was infiltrated into the surgical site post surgically at two-day intervals for two weeks and for patient 2 autologous PRP clot was placed in the gap of the defect during surgery. Post-surgically immobilisation and exercise limitation were observed for the first few weeks. A Co-ban bandage was used to support immobilisation. Both cases were followed up to one month and complete wound healing and totally functional and significant anatomical restoration of the affected limb were recorded. In comparison with previous reports of sole treatment which is surgical intervention, the recovery period was much less and effective with the combination of surgical intervention and PRP treatment. Therefore, it is justified to recommend a combination of surgical correction with PRP therapy for correcting Achilles tendon rupture for a speedy recovery.

Keywords: Achilles Tendon, Platelet Rich Plasma, Regenerative medicine

Cardiac Rhabdomyosarcoma in a Doe: A case report

G.M. Vidura¹, Y.K. Jayawardana¹, B.M.D.N. Kularatne¹, W.P.P.S.I. Perera¹, P.G.A.S. Palkumbura², R.R.M.K.K. Wjesundara², P.G.A. Pushpakumara¹ and G.D.R.K. Perera^{1*}

¹*Department of Farm Animal Production and Health,*

²*Department of Veterinary Pathobiology, Faculty of Veterinary Medicine and Animal Science, University of Peradeniya*

*Corresponding Author: gdrkperera@gmail.com

Cardiac rhabdomyosarcoma is a life-threatening and aberrant condition among goats. This paper describes an incidence of a rare case in a one and half-year-old, Saanen doe (1st parity) from an intensively managed up-country farm. The animal was presented to the Farm Animal Teaching Hospital with the complaint of distended abdomen and hyporexia over four days. On clinical examination the goat was hypothermic (98.8 F), tachypneic (70/beats per min), dyspneic, reluctant to stand, and depressed with pale mucus membranes. Auscultation revealed cardiac arrhythmia with immeasurable tachypnea due to the complexity of respiratory and cardiac dysfunction. Further, bilateral enlargement of the abdomen with fluid waves was identified on percussion. The animal was admitted for further investigations; however, the doe died, shortly after. At the autopsy, the carcass was pale. Approximately 50 ml of clear pericardial fluid and whitish vegetative growths with a cauliflower-like appearance were observed on the base of the tricuspid valve cusps. Apart from that, multifocal, petechial haemorrhages were observed in the trachea. The lungs were heavy and filled with frothy fluid. Ascitic fluid was observed in the abdomen (~5000ml). Blunt edges and fibrinous strands were observed on the liver surface. On the cut surface, there were dark irregular areas of hepatic tissue interspersed with pale areas (chronic passive congestion of liver with 'nutmeg appearance'). Pinpoint haemorrhages were observed on the serosal surfaces of the bladder and the vulva. Histopathology revealed that the vegetative growth consists of haphazardly oriented, loosely arranged tadpole/spindle-shaped or round pleomorphic large neoplastic striated muscle cells. Histopathological findings are suggestive of primary cardiac rhabdomyosarcoma and the presence of large bizarre tumour cells and deeply eosinophilic cytoplasm are evidential for the pleomorphic subtype of cardiac rhabdomyosarcoma. Immunohistochemistry could be used to confirm the histopathological features. Cardiac tumours should not be excluded in the differential diagnosis of goats with such a clinical presentation. As an indeed rare and fatal condition, early detection by clinical findings and ancillary diagnostics tests would be useful for management decisions, avoiding economic loss to the farmer in goat farming practice.

Keywords: Cardiac Rhabdomyosarcoma, Neoplasm, Cardiac tumours

Multiple Trichoepitheliomas in a Cross-bred Dog: A case report

W.M.N.S. Wijesooriya^{1*}, S. Kabilan¹, H.M.S. Wijekoon¹, K.K. Wijesundera², P.G.A.S. Palkumbura² and H. Ariyaratna¹

¹*Department of Veterinary Clinical Sciences, Faculty of Veterinary Medicine & Animal Science, University of Peradeniya*

²*Department of Veterinary Pathobiology, Faculty of Veterinary Medicine & Animal Science, University of Peradeniya*

*Corresponding Author: sewwandiwijesooriya7@gmail.com

Trichoepitheliomas are benign cutaneous neoplasms commonly found in middle-aged dogs. These tumours consist of neoplastic epithelial cells that may differentiate into hair follicles or hair shaft structures. Often, trichoepitheliomas are solitary neoplasms and multiple neoplasms are rarely reported. This article describes a case of multiple trichoepitheliomas in a 6 years old, obese, female-neutered, crossbred dog presented to the Veterinary Teaching Hospital, University of Peradeniya. The dog had three firm cutaneous masses: one on the ventral neck region and two others on the left lateral thoracic wall and distal left forelimb. The largest mass was approximately 8 × 10 cm, while the other two masses were 3 × 4 cm and 4 × 5 cm respectively. The three masses had developed sequentially over a period of three months while the largest was the first to appear. Except for mild splenomegaly, the dog was otherwise clinically normal. Fine needle aspirations were performed on all three masses which revealed tightly cohesive clusters of uniform cuboidal epithelial cells with large central nuclei and a small rim of dark basophilic cytoplasm. Multi-focally, between epithelial cell clusters, there was a pink amorphous matrix material. All three neoplasms were surgically excised with wide surgical margins and submitted for histopathology. Histopathology of all three masses was similar and revealed islands of cuboidal to columnar epithelial cells lacking apparent cytoplasmic bridges surrounded by collagenous stroma. Occasionally keratin accumulation was observed in the centre of the epithelial cell islands. The mitotic counts in all three neoplasms were less than 1 per ten high power fields. These histological features were consistent with multiple trichoepitheliomas. The surgical margins were devoid of neoplastic cells in all three neoplasms. Considering the benign features of the three neoplasms and the absence of evidence of metastasis, it was diagnosed that the masses are three separate neoplasms but not metastases. No tumour recurrence was reported during the post-surgical follow-ups. This case emphasises the necessity of using diagnostic tools including cytology and histopathology to differentiate multiple neoplasms from tumour metastasis for dogs present with multiple cutaneous masses.

Keywords: Trichoepithelioma, Neoplasm, Metastasis

Recurrent Sub-cutaneous Spindle Cell Tumour with Histological Features consistent with a Peripheral nerve sheath tumour in a 5-months-old mixed-breed dog: A case report

T.M.S.K. Piyadasa, S. Kabilan, N.B. Ramesh, H.D.S. Hewapathirana, R.M.N.S. Nuwanshika,
G.A.D.K.K. Gunathilaka, A.T. Liyanage and H. Ariyaratna*

*Department of Veterinary Clinical Sciences, Faculty of Veterinary Medicine & Animal Science,
University of Peradeniya*

*Corresponding Author: hsariyaratna@pdn.ac.lk

Peripheral nerve sheath tumours (PNSTs) are an uncommon type of spindle cell neoplasms originating from Schwann cells, perineurial fibroblasts, or both. They are often found in middle-aged to old dogs while rare in young dogs. The youngest dog reported with a PNST was four years old. This report describes a tumour present in a 5-month-old, female mixed-breed dog presented to the Veterinary Teaching Hospital, Faculty of Veterinary Medicine and Animal Science, University of Peradeniya which had histological features compatible with a PNST. The mass was present subcutaneously in the sternal area, firm, approximately 3 cm x 2 cm in size and non-painful to palpation. Except for the subcutaneous mass, the dog was otherwise healthy. The differentials considered were foreign body granuloma, follicular cyst, excessive granulation tissue formation, nodular panniculitis and cutaneous hamartoma. Fine needle aspiration cytology of the mass revealed a population of spindle cells with moderate cellular and nuclear atypia in the absence of concurrent inflammation. The subcutaneous mass was surgically excised, but the owner did not opt for histopathology. The dog was presented again when it was 7-months old for a suspected recurrence of the same sub-cutaneous mass which was 16.5 cm x 15 cm in size. The mass was surgically resected again and sent for histopathology. Microscopically, the mass was a well-circumscribed but poorly encapsulated neoplasm composed of a moderately atypical population of spindle cells. The spindle cells were arranged in two distinct, alternating patterns: hypercellular Antoni A areas and hypocellular Antoni B areas. Antoni A areas were composed of spindle cells with wavy and oval nuclei, eosinophilic cytoplasm, and indistinct cytoplasmic borders arranged often demonstrating a palisading pattern. Antoni B areas were hypocellular and less compact than Antoni A areas. They consisted of haphazardly arranged spindle cells in a loose myxoid matrix containing a few inflammatory cells and delicate collagen fibres. Multifocally, there were areas that closely resembled verocay bodies. The mitotic rate was 3/10 HPFs. No tumour recurrence was reported after the second tumour excision. This is the first report of a PNST in a young dog less than one-year-old to the authors' knowledge.

Keywords: Peripheral nerve sheath tumours, Antoni A and B, Verocay body

Immune-mediated Haemolytic Anaemia in Dogs: A One-year Retrospective Survey at the Veterinary Teaching Hospital, Peradeniya

B.M.L.N. Bandaranayaka*, K.A.R.K. Perera, E.R.K.V. Edirimanne, D.R.A. Dissanayaka and H. Ariyaratna

Department of Veterinary Clinical Sciences, Faculty of Veterinary Medicine & Animal Science, University of Peradeniya

**Corresponding Author: nishadibandaranayaka@gmail.com*

Immune-mediated haemolytic anaemia (IMHA) is caused by an autoimmune response, directed at antigens expressed on the erythrocyte surface, causing intra or extravascular haemolysis, resulting in anaemia. It is a common canine haematological disorder with an approximately 70% mortality rate. IMHA could be primary or secondary according to the causative agent of haemolysis. No previous studies have systematically investigated IMHA in dogs in Sri Lanka. This study describes the findings of a one-year, retrospective survey on canine IMHA cases presented to the VTH. The disease was often diagnosed in males (n = 40, 63.5%) and dogs aged 1-5 years (n = 23, 36.5%), overrepresentation of Labrador Retrievers and Rottweilers. Either hyporexia or anorexia was the presenting complaint of all affected dogs while vomiting, diarrhoea, abdominal distention, epistaxis, incoordination, haematuria and dyspnoea were reported in a minority of dogs. The most common clinical examination findings were pale mucosae (n = 41, 65.1 %), bounding pulse (n = 37), fever (n = 28), and jaundice (n = 17). Most dogs were severely (n = 53, 84.1%) or moderately anaemic (n = 8, 12.7%) while anaemia was regenerative in 27 of them. Of the haematological findings suggestive of IMHA, spherocytes were found in all dogs. Additionally, ghost cells were reported in 31(49.2%) dogs and micro/microagglutination 5 (7.9%) and erythrophagocytosis 1 (1.6%) were rarely reported. Concurrent anaemia and thrombocytopenia were reported in 16 (25.4%) dogs. In 41(65.1%) dogs, haemoparasites including *Babesia gibsoni*, 33(52.4%), microfilaria 6(9.5%), *Ehrlichia canis* 1(1.6%) and *Hepatozoon canis* 1(1.6%) were reported. Nine dogs (14.3%) had a history of previous treatments for haemoparasites with imidocarb dipropionate, diaminazine aceturate or oxytetracycline while there were 2 dogs treated with antibiotics and a single dog was given erythropoietin. Most dogs included in this study had concurrent haemoparasitisms suggesting haemoparasitism is a possible cause of IMHA although it cannot be confirmed due to incomplete post-treatment follow-up data. Further, it is obscure whether the drugs used to treat haemoparasitisms caused IMHA as some dogs had been treated for haemoparasitism previously.

Keywords: Immune-mediated haemolytic anaemia, Hemoparasitism, *Babesia gibsoni*

Cytological Diagnosis of a Sinonasal carcinoma in a German Shepherd Dog: A case report

W.M.N.S. Wijesooriya*, W.R.J.P. Walpola, A.T. Liyanage, A. Dangolla, D.D.N. De Silva,
H.M.S. Wijekoon and H. Ariyaratne

*Department of Veterinary Clinical Sciences, Faculty of Veterinary Medicine and Animal Sciences,
University of Peradeniya*

**Corresponding Author: sewwandiwijesooriya7@gmail.com*

Sinonasal carcinoma is an uncommon tumour in dogs originating from the lining epithelium of the nasal cavity, sinuses or serous and mucous glands in the upper respiratory tract. Generally, cytological diagnosis of sinonasal tumours is difficult mostly due to difficulty in obtaining samples of diagnostic quality. This article describes a case of sinonasal carcinoma in a 5 years old, female-intact, German shepherd dog presented to the Veterinary Teaching Hospital, University of Peradeniya diagnosed by cytology. The dog had a soft tissue swelling on the forehead approximately 3 × 3 cm in size which developed over a period of 3 months. During this period, the dog had been presented to a regional veterinary practice where it was attempted to aspirate the mass without any success. At the time of presentation, the dog had obstructive breathing pattern with an inspiratory stridor. In addition, there was exophthalmos in the right eye with bilaterally hyperaemic conjunctiva and oral mucous membranes. Radiographs of the cranium revealed a soft tissue mass in the frontal area with an incomplete frontal bone lysis. Fine needle aspiration biopsy was obtained from the mass which was highly mucoid and light yellowish in colour. Microscopic examination of the aspirated contents revealed an atypical population of epithelial cells arranged in variably sized clusters in a haemodiluted background with windrowing. The cells were round to polygonal and had large, round central nuclei. Frequently there were prominent nucleoli. The cytoplasm of the cells often contained variably sized vacuoles with indistinct borders. The background contained lightly basophilic amorphous material which was consistent with mucus. The anisocytosis and anisokariosis of the epithelial cell population was moderate to high. Considering the location of the lesion, clinical signs and cytological findings a diagnosis of sinonasal carcinoma was attempted. Tumour was surgically excised and drainage was applied. Histopathology was unable to perform due to the highly fragile nature of the excised tumour. In the post-surgical follow ups, a mild improvement in the breathing pattern was observed. The owner did not consent to post-surgical chemotherapy.

Keywords: Sinonasal carcinoma, Exophthalmos, Windrowing

Cutaneous Asthenia (collagen dysplasia) in a Rottweiler

K.A.R.K. Perera*, T. Apinaiyaa, K.A.N. Wijayawardhane, H.M.S Wijekoon and
D.D.N. de Silva

*Department of Veterinary Clinical Sciences, Faculty of Veterinary Medicine & Animal Science,
University of Peradeniya*

**Corresponding Author: rkperera27@gmail.com*

Cutaneous asthenia in dogs is a hereditary connective tissue disorder that is similar to Ehlers-Danlos syndrome in humans. It is also known as hyperelastosis cutis, dermatosparaxis and collagen dysplasia disease. It is autosomal dominant and caused by a mutation in the connective tissue gene. This mutation affects collagen type I and III synthesis resulting in a lack of tensile strength, especially in skin, joints and ligaments. This has also been reported in cats, mink, horses, cattle, and sheep. Clinically it is characterized by hyper-extensibility of the skin and minor trauma could result in lacerations and large wounds. Boxer, Dachshund, Greyhound, Beagle, English springer spaniel, Saint Bernard, German Shepherd are the commonly affected, but it has not been reported in Rottweilers. The present case was a 10-month-old male Rottweiler presented to the Veterinary Teaching Hospital, University of Peradeniya with the complaint of non-healing large wounds near joints and perineal region over a period of 3 months. Clinical examination revealed that the skin could be stretched to extreme lengths and hanging loosely in folds, lacerations were evident particularly near joints of the limbs. There is no differential diagnosis that mirrors this distinct syndrome in dogs. In this case, the diagnosis was based mostly on history and clinical signs supported by histological examination of skin biopsy from the perineal region. Skin scrapings were negative for ectoparasites and moderate bacterial infection was observed. Histology of the skin revealed abnormal collagen fibres characterized by disorganised, short, uneven, collagen fibres with wide interfibrillar spaces which were suggestive of collagenolysis. No specific treatment has been reported in dogs although oral administration of vitamin C has been suggested since it is necessary for collagen synthesis. Moreover, surgical excision and closure to remove extra hyperelastic skin folds and antibiotics for wound healing can be used. However, these treatments were not successful in this case and complications like suture dehiscence resulting in larger gaping wounds with delayed wound healing were observed. As there were no other treatment options available, the dog was euthanized with the owner's consent. It could be concluded that cutaneous asthenia is a condition with a poor prognosis.

Keywords: Cutaneous Asthenia, Rottweiler, Hyper-extensibility, Collagen, Collagenolysis

Soft Tissue Sarcomas in dogs: Two case reports

B.M.L.N. Bandaranayaka*, W.R.J.P. Walpola, A.T. Liyanage, T.M.S.K. Piyadasa, C. Abeykoon,
H.M.S. Wijekoon, E.R.K.V. Edirimanne and D.D.N. de Silva

Veterinary Teaching Hospital, Department of Veterinary Clinical Sciences, Faculty of Veterinary Medicine and & Animal Science, University of Peradeniya, Peradeniya, Sri Lanka

*Corresponding Author: nishadibandaranayaka@gmail.com

Soft tissue sarcomas (STSs) are mesenchymal neoplasms derived from soft tissues. Most STSs are solitary tumors with no breed or sex predilection and the treatment of choice is surgical resection. Local recurrence rates are low but vary, depending on histologic grade and completeness of surgical margins. This communication is based on two different STSs presented to the Veterinary Teaching Hospital, Peradeniya. Both patients were 6 years old intact German shepherd males. Patient 1 (P1) had a gradually enlarging lump on the right side over the iliac crest for four months while patient 2 (P2) had a gradually enlarging abdomen and reduced appetite for two weeks. In both dogs' clinical examination revealed hyperthermia; 102.8 °F in P1 and 103.2 °F in P2 and bounding pulse. Full blood count of P1 was unremarkable while P2 had thrombocytopenia (94000/ μ l) and anaemia PCV (23.3%). Radiography of P1 revealed an ovoid mass with soft tissue opacity surrounding the last four lumbar vertebrae on the right side. Abdominal ultrasonography of P2 revealed a moderately vascularized mass having mixed echogenicity; occupying a large area of the abdominal cavity. Surgical excision of the masses was proposed. The mass of P1 was attached to the transverse processes of the lumbar vertebrae and other margins were well defined. In P2 the mass was freely located in the abdomen surrounded by mesentery, but one side of the mass was located over the caudal vena cava. The weight of masses was 2.2kg in P1 and 7.1kg in P2. Gross pathological examination of cut surfaces revealed light pinkish colour and firm consistency. Histopathological examination of both cases were having spindle cells in dense collagen matrix in P1 while cells in P2 arranged into compact sheaths and occasionally loose short interwoven fascicles. Both had indistinct cell borders and nucleoli with finely stippled chromatin. Both are grade I tumors according to the histological grading. This report reviews the cytologic, histological, pathological and clinical appearance of two presentations. Even though STSs are unspecified with breed, age and sex, both these patients were in the same age and male German Shepherds.

Keywords: Soft tissue sarcomas, Solitary tumors, Mesenchymal neoplasms

High Grade Sarcoma of the Maxilla in a one-year-old Labrador Retriever: A case report

A.T. Liyanage*, W.M.N.S. Wjesooriya, T.M.S.K. Piyadasa, W.P. Walpola, H. Ariyaratna,
H.M.S. Wijekoon and D.D.N. de Silva

*Department of Veterinary Clinical Sciences, Faculty of Veterinary Medicine and Animal Science,
University of Peradeniya, Sri Lanka*

**Corresponding Author: ashanliyanage500@gmail.com*

Malignant oral neoplasms are rarely reported in young dogs. The most common method of treatment of oral tumours in dogs is local surgical excision, although this is often unsuccessful due to tumour recurrence at the surgical site. This report describes an oral tumour diagnosed as a high-grade sarcoma in a one-year-old, female Labrador retriever presented to the Veterinary Teaching Hospital, University of Peradeniya. The presenting complaint was difficulty in breathing. The general clinical examination revealed a severely erythematous and ulcerative oral mass approximately of 7 cm x 2.5 cm size spanning the upper palate developed in a one month period. The differential diagnoses for the mass lesion included foreign body granuloma, giant cell granuloma and transmissible venereal tumour. Other types of oral neoplasms were considered less likely due to the young age of the dog. Fine needle aspirates obtained from the mass were highly hemodiluted and therefore non-diagnostic. Radiographs of the skull did not show bone lysis and other routine haematological and biochemical profiles were within the normal limits. As the mass showed rapid growth despite the treatments with antibiotics and anti-inflammatory drugs, it was surgically excised under general anaesthesia. The histopathology of the mass revealed a highly atypical population of mesenchymal cells arranged in herring bone pattern and occasionally short fascicles and sheets. The cellular and nuclear pleomorphism were high and the mitotic rate was 3 per 10 high power fields. Occasionally there were giant cells. No significant inflammation was observed within the neoplasm. The histological features were mostly consistent with a high-grade sarcoma and the differentials included fibrosarcoma and osteoblastic fibrosarcoma. After one-week of surgery, the patient was presented again for tumour recurrence. Surgical tumour resection was not attempted this time due to the limited ability of complete tumour excision and the deteriorated condition of the patient. Other treatments for oral sarcomas include radiation therapy and chemotherapy. However, the owner did not opt for chemotherapy and radiotherapy is not available in Sri Lanka. Oral sarcomas with aggressive behaviour like the present case are uncommon and extremely rarely reported in young dogs.

Keywords: Sarcoma, Radiation therapy, Osteosarcoma

Intestinal Phytobezoar in a Goat: A case report

B.M.D.N. Kularatne, B.I.U. Perera, G.M. Vidura, Y.K. Jayawardana, H.E.L. De Seram, P.G.A. Pushpakumara and G.D.R.K. Perera*

Department of Farm Animal Production and Health, Faculty of Veterinary Medicine and Animal Science, University of Peradeniya

*Corresponding Author: gdrkperera@gmail.com

Phytobezoars are aggregated fiber materials with plant origin. Although phytobezoars are the most common type of bezoars reported in the forestomach or the cecum, intestinal obstructions due to phytobezoars are rare in goats managed under local farming conditions. This paper describes the clinical manifestation, diagnosis, and treatment of such obstruction with an intestinal phytobezoar in a doe goat. A three-year-old Saanen doe was referred to the Farm Animal Teaching Hospital, Faculty of Veterinary Medicine and Animal Science with a complaint of off-feed for eight days and absence of defecation for few days, under the usual management conditions without any dietary changes. The physical examination revealed normal body temperature (103.2 °F), heart rate (82 beats per minute), respiratory rate (22 breaths per minute), and pink mucous membrane with mild dehydration. An elongated hard mass, which could be palpated from the left and right paralumbar fossa, was in the caudo-dorsal region of the abdomen. Radiographs of the left lateral abdomen confirmed a radio dense elongated structure localized in the ascending colon. A left flank laparotomy followed by an enterotomy was conducted to remove the mass under general anesthesia using Xylazine (0.02 mg/kg, intramuscular) and Ketamine (11mg/kg, intravenous). The mass was made up of plant fibers, and it was cylindrical with approximately 14 cm in length and 12 cm in circumferences. Detailed examination of a longitudinal section of this peculiarly shaped structure confirmed a phytobezoar with a lamellar arrangement of plant fibers without a nidus. The non-viable intestinal tissues adjacent to the phytobezoar were resected, and the remaining viable intestinal sections were anastomosed before the laparotomy closure. Phytobezoar lodged in the forestomach or the cecum in small ruminants usually does not cause complications; however, the intestinal phytobezoar might cause severe life-threatening complications. Although this is a rare condition among goats, it is necessary to include phytobezoar in the list of differential diagnoses when an animal is presented with a history of absence of defecation.

Keywords: Phytobezoar, Intestinal obstruction, Left flank laparotomy

Tetanus in a dog – Successful outcome of the treatment: A case report

B.R.Nirujan, S. Kabilan and K.A.N. Wijayawardhane*

Department of Veterinary Clinical Sciences, Faculty of Veterinary Medicine and Animal Sciences, University of Peradeniya

*Corresponding Author: nwijayawardhane@yahoo.com

Tetanus is a relatively uncommon disease in dogs due to their natural resistance to the neuro toxin. Here, we report the outcome of treatment of a dog diagnosed with tetanus. A 3-year-old male crossbred dog was presented to the Veterinary Teaching Hospital with a two-day history of loss of appetite, and stiffness fore limbs. On physical examination, the patient was alert, recumbent, fore limbs were stiff, neck and tail hyperextended, ears were erect, facial muscles were contracted with retracted lips, lock-jaw, protruding nictitating membranes and enophthalmos. Lacerations due to barb-wire fence were detected in both hind limbs. In addition, Hyperthermia, seizures, mild congestion in lungs, and arrhythmia were present on admission. A presumptive diagnosis of tetanus was made based on the history and characteristic clinical signs. The dog was hospitalized in a darkened and quiet room. Benzyl penicillin 20000 IU/kg, twice daily, midazolam 0.2mg/kg every 3 hours and metronidazole 10 mg/kg twice daily were given intravenously for 2 weeks. About 45ml of serum containing tetanus antitoxin transfusion was given in a slow drip via intravenous route. Tetanus antitoxin helps in neutralizing the toxin in the bloodstream. Benzyl penicillin was used to eliminate vegetative *Clostridium tetani* organisms and to prevent further toxin formation. Metronidazole was used to combat complications due to anaerobic organisms. Midazolam was used as a muscle relaxant and to prevent seizures. Intensive nursing care was provided with feeding through nasogastric tube, facilitation of breathing, monitoring of urination, defecation and frequent changing of positions to prevent decubitus ulcer formation. The patient was well hydrated, and physiotherapy was provided by massaging and manual extension and flexion of joints. Physiotherapy was used to improved blood supply and lymphatic drainage from the muscles while relaxing spastic muscles and relieving discomfort. The muscle rigidity was still very marked after the first week of hospitalization and the animal was unable to rise, eat or drink unassisted. Tetanus appears to be guarded with slow recovery, where it may take several weeks before the animal becomes ambulatory. This patient attempted sternal recumbency and began defecating and urinating after a week of intensive treatment regime. By ninth day of treatment, patient started to crawl and later tried to stand without the help of harness. On the thirteenth day, patient started to walk to the call of his owner.

Keywords: Tetanus, Neurotoxin, Recumbent

Effect of Intra-articular injections of Platelet Rich Plasma (PRP) for Lameness in Dogs with Osteoarthritis of the Coxofemoral Joints

M.G.T.M. Prasadinie*, H.D.S. Hewapathirana, D.D.N de Silva and H.M.S. Wijekoon

Department of Veterinary Clinical Sciences, Faculty of Veterinary Medicine and Animal Science, University of Peradeniya

**Corresponding Author: tharindikamaninali10@gmail.com*

Canine autologous platelet-rich plasma (PRP) is a biological preparation made from the patient's own plasma that contains a platelet concentration exceeding the baseline values of the whole blood. Osteoarthritis (OA) is the most diagnosed joint disease in veterinary medicine, characterized by its inflammatory character and degradation of cartilage layers. Management of OA is challenging due to its multifactorial causes. PRP is an efficient treatment option for OA in numerous species due to its potential anabolic and anticatabolic effects and the ease of preparation. In this study, efficacy of PRP was evaluated by giving intra-articular injections into osteoarthritic hip in 3 dogs presented to Veterinary Teaching Hospital, Peradeniya with average age of 5.2 years and average body weight of 31.3 kg. All the patients presented with a complaint of difficulty in walking. Joint involvement and the severity were assessed by physical examination and radiographs of the affected limbs. All the 3 dogs underwent routine clinical biochemistry and hematology evaluation to ensure overall health. All the dogs received an intra-articular (IA) injection of 2ml of PRP in affected hip joint on day 0, 14 and 28. All the cases followed up for 42 days after first IA PRP injection. Limb function in the dogs before PRP therapy and 6 weeks after first PRP injection was evaluated using a veterinary orthopedic examination assessment score sheet. Clinical lameness scores were assigned based on visual examination of gait at a walk and trot, pain on passive manipulation of the affected joint and limited range of motion with pain at less than full range of passive motion and functional disabilities; including level of stiffness as measured by willingness to walk and run. Radiographic scores were determined for each dog based on a radiographic scoring scale. Results were analyzed and it demonstrates that IA PRP therapy resulted in significant improvement in lameness, range of motion, and pain on manipulation, as well as overall combined scores of dogs over time. This study shows that intra-articular administration of PRP therapy decreases patient discomfort and increases patient functional ability.

Keywords: Intra-articular injections, Lameness, Osteoarthritis, Platelet rich plasma

Possible Breed Predisposition in Vestibular Syndrome (Vs) using data collected at Veterinary Teaching Hospital, Peradeniya

E. Bernard and A. Dangolla*

Department of Veterinary Clinical Science, University of Peradeniya, Peradeniya

**Corresponding Author: adangolla@gmail.com*

All dogs reported to Veterinary Teaching Hospital (VTH) with suspected clinical signs of Vestibular Syndrome (VS) from 1st January 2016 to 1st January 2018 were perused with the objective of examining from 1st January 2016 to 1st January 2018 were perused to examine possible breed predisposition. Presence The presence of two or all of the following 3 clinical signs at presentation was defined as VS, different degrees of gait problems with balance maintaining issues (circling, falling, rolling), changes in the position of the head (tilt, rotation, acceleration, deceleration) and any type of nystagmus (horizontal, vertical or rotatory). Any dog with either clinically or hematologically detectable any other ailments was excluded. A total of 8748 dogs were reported during the period, out of which 65(0.7%) was suspected of VS. The proportions of dog breeds in their decreasing order with respective breed breed-specific proportions of VS were; cross bred (46%,0.4%), German shepherd (22%, 0.4%) Rotweiller (7.1%,3.4%), Labrador (6.4%,1.1%), Doberman (3%, 3.8%) and Dalmatian (1.8%,3.2%). A total of 16 other breeds (n=265) did not report even a single VS suspected case. When crossbreed was used as the comparison, the German Shepherd, Rotweiller, Labrador, Doberman and Dalmatian breeds had odds of 0.9,7,2,9 and 7, respectively and all other breeds collectively had an odds ratio of 4. All cases had been treated with different combinations of osmotic diuretics, fluids, sedatives, antibiotic ear drops with or without steroids and parenteral antibiotics. Numbers The numbers of hospitalised cases, recurrences and case fatality fatalities could not be traced. In VTH, VS is a rare condition, most frequently reported in Dobermans. German Shepherds apparently has the lowest odds of developing VS. Increasing pure breed popularity, constant awareness on dog health issues and clients affordability for treatment at VTH may have contributed to results. The VTH being a referral hospital and clients are compelled to wait for a relatively long time, both of which would have influenced observed data. Clinicians must consider Horner's syndrome in the diagnosis of VS in this regard since it has also been reported at VTH.

Keywords: Breed Predisposition, Vestibular syndrome, Balance maintaining issues

Concurrent occurrence of High-Grade Mast Cell Tumour and Hepatoid Gland Adenoma in a young male Labrador Retriever

W.R.J.P. Walpola*, K.A.R.K. Perera, H.D.S. Hewapathirana, I.P.C.S. Kithsiri, A.T. Liyanage, S.U. Abeyrathne, H.M.S. Wijekoon and D.D.N. de Silva

¹*Department of Veterinary Clinical Sciences, Faculty of Veterinary Medicine and Animal Science, University of Peradeniya*

**Corresponding Author: wrjayaminipabasara@gmail.com*

Mast cell tumours (MCTs) are the most diagnosed cutaneous tumors which occur in cutaneous and subcutaneous tissues anywhere in dogs. Golden Retrievers, Labrador Retrievers, Boston Terriers, Boxers and Pugs are predisposed to these tumours. Hepatoid Gland Adenomas (HGA) accounts for about 10% of the canine skin neoplasms and their growth is influenced by sex hormones in intact males. This study describes the high-grade MCT with concurrent HGA in a 2 ½ years old, male Labrador Retriever presented to the Veterinary Teaching Hospital with a history of rapidly growing, pink peri-anal masses. Of the two masses, one was approximately 2cm diameter, multilobulated, erythematous and present on the skin just above the anus (mass A). The other mass (mass B) was present on 7'clock position of peri-anal area, approximately 1cm diameter and the color and consistency similar to mass A. Fine needle aspiration (FNA) of mass A revealed a mixed population of inflammatory cells including mast cells while mass B was consistent with a hepatoid gland neoplasia. Both masses were surgically excised. Histopathology of mass A revealed an encapsulated, partially circumscribed neoplasm composed of sheets of round cells streaming along a moderately thick fibrovascular collagenous stroma. The nuclei were rounded and occasional binucleated cells and mitotic figures were present. These features were consistent with a high-grade MCT. Mass B was a well circumscribed, unencapsulated, densely cellular neoplasm composed of uniform broad trabeculae and islands of polygonal cells surrounded by a single layer of attenuated basaloid reserve cells supported by a delicate fibrovascular stroma. The nuclear pleomorphism of mass B cells was minimum and the histological features were consistent with HGA. The biological behavior of malignant MCT is highly unpredictable. Distant metastasis to spleen, lymph nodes, skin and bone marrow is possible, but combination of surgical resection with chemotherapy or radiotherapy may increase the chance of survival. Follow up was done after 2 weeks of surgery. Presence of more growths was observed along the dorsum and both sides of the neck, which were also confirmed as MCT. Recurrence is typical with HGA, but no recurrence until the last follow up.

Keywords: Mast Cell Tumor, Hepatoid Gland Adenoma, Metastasis

Enucleation of a ‘Khilari’ Bull under the Field Condition: A Rare Case of Lacrimal Gland Neoplasia

W.P.P.S.I. Perera¹, W.M.T.D. Ratnakumara¹, P.G.A.S. Palkumbura², R.R.M.K.K. Wjesundara², G.D.R.K. Perera^{1*} and A.A.A.W.K. Amarasinghe¹

¹*Department of Farm Animal Production and Health, Faculty of Veterinary Medicine and Animal Science, University of Peradeniya*

²*Department of Veterinary Pathobiology, Faculty of Veterinary Medicine and Animal Science, University of Peradeniya*

*Corresponding Author: gdrkperera@gmail.com

Bovine ocular carcinomas are rare in which adenoid cystic carcinoma, primary adenocarcinoma and pleomorphic adenomas are considered extremely rare. This paper describes an incidence of such a case in an 11-year-old (approximately 600kg) “Khilari” bull. The bull was presented to the Ambulatory Clinic with the complaint of a gradually developing mass on the left eye (medio-ventrally) over the past six months period. A light pink mass (length-6cm, width-4cm) was identified on the palpebral and bulbar conjunctiva with severe epiphora. Intra-lesion Vincristine sulfate (0.2ml) and methylprednisolone (1ml) was injected in 14 days intervals for 2 two months. Due to the aggravation of the condition covering the eye site, enucleation was carried out. The procedure was carried out *in-situ* under heavy sedation with Xylazine (0.1mg/kg, intramuscularly), and retrobulbar block with 2% lignocaine (10ml/ site for 4 sites) at right lateral recumbency. With the indication of the full block by exophthalmosexophthalmos, corneal anaesthesia, and mydriasis, tarsorrhaphy was done and elliptical transpalpebral incisions were made at the level of the orbital border. The optic stalk was severed and the dead space was drained using a Penrose drain. The skin incision was sutured using No. 0.45 nylon with a ford interlocking pattern. Procaine benzylpenicillin (20mg/kg) and ketoprofen (0.2mg/kg) injections were given once daily for seven and three days, respectively, in the intramuscular route. Penrose drain was removed after two weeks under mild sedation. After two weeks under mild sedation, the Penrose drain was removed with 2% Xylazine (0.05mg/kg). Histopathology revealed neoplastic proliferation of lacrimal gland epithelial and myoepithelial cells. Furthermore, neoplastic cells were arranged in sheets and prominent gland formation. Areas of neoplasm showed cystic changes. High mitotic index and high cellular nuclear atypia were observed. With histological features, it was diagnosed as an adenoid cystic carcinoma with features of primary adenocarcinoma and pleomorphic adenoma. Immunohistochemistry will warrant further differentiation of the tumour. Follow-up after the twelve months from the surgery After twelve months of surgery, follow-up revealed, the bull has had been used for the routine without any secondary health issues of the neoplasia. Early decisions and an accurate treatment plan would be highly effective for the treatment of tumour conditions.

Keywords: Khilari, Ocular carcinoma, Neoplasia

A Case of Chronic Urinary Retention

S.U.G. Amarasena, K.A.N. Wijayawardhane*, D.D.N de Silva and H.M.K. Dananjaya

Department of Veterinary Clinical Sciences, Faculty of Veterinary Medicine and Animal Science, University of Peradeniya

*Corresponding Author: nwijayawardhane@yahoo.com

An 8-year-old female dog was presented to the Veterinary Teaching Hospital (VTH) with a 2-month history of enlarged abdomen and stranguria. The first symptoms had been dysuria and oliguria. Subsequently, the dog developed complete urinary retention. Clinical examination at VTH, revealed severe abdominal distension with a non-painful (on palpation) distended rock-hard bladder occupying almost entire abdomen. Ultrasonography indicated a thick bladder wall and hyper echoic material in the bladder. Neither manual bladder compression nor the insertion of the female urinary catheter was possible due to resistance felt in the urethra. Thus, cystocentesis was performed using a 21G needle and as a result, 7l of urine was removed. A sterile urine sample was submitted for urinalysis, bacterial culture and antibiotic sensitivity testing (ABST). The culture of the sample yielded a *Escherichia coli* dominant mixed growth and intravenous Amikacin (20mg/Kg, once a day) was administered for 2 weeks based on the ABST results. Subsequent ABST revealed the emergence of antimicrobial resistance therefore, amikacin was replaced with oral nitrofurantoin. During the first day, cystocentesis had to be performed which was later coupled with sterile catheterization. During catheterization in the proximal urethra, and to minimize repeated trauma, a female catheter was permanently fixed to the vaginal wall for urine drainage into an attached urine bag. However, severe straining prevented smooth urine drainage into the bag and catheterization had to be daily performed. Since the animal appeared to have had functional urethral obstruction, tamsulosin 10µg/kg, once daily (act on the alpha 1A receptors on internal and external urethral sphincters), diazepam 0.2mg/kg, twice a day (external urethral sphincter muscle relaxant) metoclopramide 0.2mg/kg, twice a day (to overcome the direct damage to the detrusor muscles due to the over-distention of bladder) and nitrofurantoin (5mg/kg, twice a day) were used for further one month. Since the urine culture did not yield growth after 1 month, antibiotic treatment was discontinued. Animal fully recovered after 10 weeks after treatment. This communication highlights the need for a diagnostic plan and intensive treatment and management practice to successfully treating atonic bladder.

Keywords: Chronic urinary retention, Atonic bladder, Stranguria

Antimicrobial Resistant Pattern of *Staphylococcus* Species Isolated from Canine Pyoderma

M.L.W.P. De Silva¹, K.S.A. Kottawatta¹, R.S. Kalupahana¹, P.G.A. Pushpakumara¹, C.B. Riley²
and K.A.N. Wijayawardhane^{1*}

¹Faculty of Veterinary Medicine and Animal Science, University of Peradeniya, Sri Lanka

²School of Veterinary Science, Massey University, New Zealand

*Corresponding Author: nwijayawardhane@yahoo.com

Antimicrobial Resistance (AMR) is a chief health concern worldwide. “One Health” approach is favoured to combat this problem as the use of antimicrobials is common in both humans and animals. Further, companion animals are considered as a potential risk that favours inter-species transmission of AMR bacteria. One of the most common conditions that require frequent antimicrobial treatment is canine pyoderma. The predominant aetiological agent in pyoderma is *Staphylococcus* spp. The objective of this study was to identify the AMR patterns of *Staphylococcus* isolates from canine pyoderma, presented to the Veterinary Teaching Hospital, University of Peradeniya. Two hundred and five samples were collected via skin swabs from dogs presented with signs of pyoderma. Isolation and identification of isolates were performed by standard culture methods, Gram staining and biochemical tests. *Staphylococcus* was isolated from 87.8% (180/205) samples. Antibiotic susceptibility testing (ABST) was carried out for 171 isolates by disk diffusion method following CLSI guidelines for nine clinically relevant antimicrobials. AMR was most commonly found for penicillin (74.9%), tetracycline (44.4%), erythromycin (43.9%), clindamycin (40.4%) and ceftiofur (31.0%). Resistance against other tested antibiotics was sulfamethoxazole-trimethoprim (25.7%), ciprofloxacin (11.7%), gentamycin (11.1%) and amikacin (7.5%). Human methicillin resistant *Staphylococcal* infections have been managed with aminoglycosides like amikacin. However, alarmingly 7.5% of canine isolates were resistant to amikacin. Moreover, 48.0% (82/171) of the isolates showed multiple drug resistance (MDR) including 37 different MDR patterns. MDR was considered as resistance against at least for three different antibacterial classes. Literature witnesses the correlation between the use of antibiotics and emergence of AMR. Thus, as there are other underlying primary causes (eg., ectoparasites, allergies) for canine pyoderma, proper diagnosis is crucial and ABST should be done as necessary for the prudent use of antibiotics. In conclusion, AMR and MDR is a significant problem for canine *Staphylococcal* isolates recovered from cases of pyoderma. Further investigation of antimicrobial use and other contributing factors for the development of resistance in members of this genus in Sri Lankan dogs is warranted.

Keywords: Antimicrobial resistance, Multiple drug resistance, Canine pyoderma, *Staphylococcus* spp

Management of Septic Peritonitis in Dogs and Cats: Primary Closure Vs Open Peritoneal Drainage

H.K.U.S. Hemachandra* and D.M. Siriwardhane

Pet Vet Clinic, 135, Kirula Road, Colombo 05

**Corresponding Author: umashas@gmail.com*

Sepsis is a frequent contributor to morbidity and mortality in small animals. Septic peritonitis is an inflammatory condition of the peritoneum, secondary to microbial contamination/toxins. It could be the result of surgical complications or bacterial translocation. Peritoneal fluid analysis is essential, as physical examination and history alone is often inadequate to diagnose. Post-operative management can be done by primary closure (PC), open peritoneal drainage (OPD) or closed suction drainage. This study will compare the success of OPD versus PC. This study follows 10 cases (3 cats and 7 dogs) presented to the hospital and includes a thorough history, physical examination, hematology and serum biochemistry. Abdominal radiographs, ultrasound and peritoneal effusion cytology were performed when definitive peritoneal contamination was not identified. Broad spectrum antimicrobial drugs, fluid and other supportive medications were administered pre-surgically. Exploratory laparotomy was performed using midazolam/ketamin as sedatives and isoflurane for maintenance. Warm sterile saline (minimum of 200 ml/kg) was used to lavage the abdomen after correcting the primary cause. Post lavage swabs for bacterial culture were collected. Either PC or OPD was used for closure. With OPD, celiotomy wound was partially closed with 2 openings. Tie over sutures were placed with dressing over the open drain. Daily abdominal lavage was done prior to abdominal closure 3-4 days after surgery. All received optimal intensive care, antibiotics, pain medications, protein supplements and fluid. Presenting complaints were postsurgical complications (n=6), Intestinal perforation (n=1), ruptured pyometra/cystic ovary (n=2) and suspected Feline Infectious Peritonitis (n=1). Four were managed with OPD and six with PC. Out of four OPDs; three recovered and one succumbed. Out of six PCs; one recovered uneventfully while the other five had to be re-opened due to re-accumulation of free fluid. Out of these five, one succumbed to septic shock. Of these four underwent secondary OPD, three recovered and one euthanized. Out of 10 cases, seven recovered completely (70% success rate). Of which, six were managed by initial/secondary OPDs (60% success) whereas only one PC was successful (16.7% success). Results were benefited by standard intensive care protocols and client compliance. The overall motility rate was 30% which is the same as with literature findings.

Keywords: Septic Peritonitis, Open Peritoneal drainage, Primary closure, Contaminated peritoneal cavity
Abdominal lavage

Treatment Trial for Non-Responsive Anemia with Surgical Removal of Retained Ovaries: A case study

H.K.U.S. Hemachandra*

Pet Vet Clinic, 135, Kirula Road, Colombo 05

**Corresponding Author: umashas@gmail.com*

“Kalu,” an eight-year-old female, native breed, sterilized (2017), up to date dewormed and vaccinated dog was presented in July 2021 with the complaint of anorexia of two weeks, mild vaginal discharge, lethargy and sporadic vomiting. She had a history of recurrence of estrous and mild vaginal bleeding five months post-surgery. She was also treated successfully with vincristine for a vaginal wall tumour later in 2017. She was treated by her local veterinarian with cotrimoxazole suspecting stump pyometra, while her abdominal ultrasound scan revealed only splenomegaly. Clinical examination revealed pale mucous membrane, splenomegaly and mucoid vaginal discharge, while haematology and serum biochemistry showed thrombocytopenia (45,000), non-responsive anemia (PCV-12; RI-0.56), ehrlichiosis, hypo-albuminemia and hyper-globulinemia. IMHA and babesiosis were ruled out from blood tests. Kalu was treated with cefuroxime, doxycycline and 3 doses of Erythropoietin (every 24h). Despite this, RI and PCV remained unchanged in daily blood tests and she progressively deteriorated. Abdominal ultrasound was repeated. In addition to splenomegaly circular hyperechoic structure was observed behind the caudal pole of the left kidney with two cysts and irregular hyperechoic structure was visible medial to the right kidney with no cyst; suggestive of left retained ovary and possible right retained ovary. Exploratory laparotomy was initiated to remove retained ovaries as Kalu showed considerable bone marrow suppression with progressive low RI and PCV despite normal WBC. A blood transfusion was done one day prior to surgery, and counts improved the next day post-transfusion (PCV- 21, Platelets-220,000 and RI -4.04). Hard sphericle shaped mass was found on both left and right ovarian stump area and two cysts were found on the left mass. Biopsy was not performed. Haematology values further improved 24h (PCV- 28), 3 days (PCV- 31) and 21 days (PCV- 32) post-surgery. According to the literature, bone marrow toxicity due to endogenous estrogen was suspected, which is possible due to ovarian granulosa cell tumor. Retained ovaries could have been sent for histopathology to confirm this etiology. This is an important differential to be aware of in the case of retained ovaries, especially is associated with chronic non-regenerative anemia.

Keywords: Non responsive anemia, Retained Ovary, Bone marrow toxicity, Endogenous estrogen, Ovarian granulosa cell tumor

Effects of Fermented Juice of Epiphytic Lactic Acid Bacteria (FJLB) on Fermentation Quality of Maize Silage

M.W.D.C. Weerathunga^{1*}, U.W.G.D.N. Udagama¹, M.P.B. Kumara Mahipala² and W.M.P.B. Weerasinghe¹

¹*Veterinary Research Institute, Gannoruwa, Peradeniya*

²*Faculty of Agriculture, University of Peradeniya*

*Corresponding Author: dilinichami@yahoo.com

Epiphytic LAB naturally occurs on the crops that are used to enhance fermentation quality of silage. The objectives of the current study were to evaluate the sensory and fermentation qualities of fodder maize ensiled with additives of fermented juice of epiphytic lactic acid bacteria (FJLB) collected from Guinea grass (*Panicum maximum*). About 165g of fresh Guinea grass were harvested before flowering, macerated with 335 ml of distilled water, filtered through a cheesecloth, 3% (w/v) of sugar added and incubated anaerobically for 3 days. Fodder Maize variety was Pacific -2075920 harvested (90 days), wilted (24h) and chopped (1 inch). Treatments consisted of three levels of added FJLB (v/w%) (T₁; 0.5, T₂; 1, T₃; 1.5%), whilst controls (C₁, C₂, C₃) consisted of the same volumes of distilled water and replicated three times. Approximately 1kg of silo was prepared from each and ensiled for 45 days. Once harvested, around 100g sub-sample of silage taken for analysis of dry matter (DM), sensory and fermentation quality (pH, lactic acid (LA) and water soluble carbohydrate (WSC). Data was analysed as one way ANOVA using the statistical software Minitab (version 16). An acidic sour vinegar smell was presented in the controls and a sweet, fruity alcoholic aroma in T₁, T₂, T₃. Increasing the concentration of FJLB of the silages gradually decreased ($p < 0.05$) pH from 4.15 in T₁ to 4.09 in T₃ and gradually increased LA concentrations from 5.61% in T₁ to 8.63% in T₃ compared with control (pH, C₁; 4.23 to C₃; 4, 16 and LA, C₁; 4.41% to C₃; 5.91% respectively). The WSC and DM contents were higher ($p < 0.05$) in C₃ (2.97% and 31.84% respectively), whereas the lowest ($p < 0.05$) was observed in T₃ (1.24% and 29.86%, respectively), suggesting enhanced utilisation of carbohydrate precursors from lactic acid bacteria when increasing the FJLB concentration. Ammonia-nitrogen production was negligible in all the treatments and controls. The results revealed that ensiling of fodder maize with additive of 1.5% FJLB, increased the lactic acid production, which resulted in lower pH, thus there was the preservation of fodder maize. Further studies are needed to determine the nutritional composition of silages and microorganisms present in the FJLB to utilise this at an industrial scale.

Keywords: Lactic Acid Bacteria, Silage, Maize

An Oestrus Synchronization Protocol Using 17-A-Hydroxyprogesterone Caproate (Proluton) on the Pregnancy Rate of Goats

**S. Premaratne¹, T. De Silva², L. Fonseka², R. Sampath³, K.M. Wimalasooriya¹,
D. Wickramasinghe¹, K. Premarathne¹, A. Olagedara¹, C. Gajaweera², S. Disnaka¹
and I. Pathirana^{2*}**

¹*National Livestock Development Board, Narahenpita, Sri Lanka*

²*Department of Animal Science, University of Ruhuna, Kamburupitiya, Sri Lanka*

³*Institute for Agro-Technology & Rural Sciences, University of Colombo, Weligatta, Sri Lanka*

**Corresponding Author: indunilvet@agri.ruh.ac.lk*

Imported progesterone (P4) impregnated devices such as CIDR® and sponges are frequently used to synchronise oestrus in goats in Sri Lanka. These devices are expensive and not affordable for rural farmers in the country. Therefore, two preliminary experiments were conducted at Kottukachchiya NLDB farm to seek an alternative, progestin-based oestrus synchronisation protocol. Based on the results of these experiments, a study was designed to investigate the efficacy of a low-cost oestrus synchronisation protocol for goats using 17- α -hydroxyprogesterone caproate (17-OHPC) and PGF2 α . Test group (n=31) comprised of Saanen does in mixed age categories. All does were kept on a high plane of nutrition for one month with commercially available cattle feed (700 g/day) and mineral and vitamin pre-mix (Aminol®; 15 g/day). Additionally, cod-liver oil (10 ml, two weeks apart), single shot of multivitamin (5 ml) and vitamin E/Se (2 ml) intramuscular injections were given before synchronisation. Each doe was administered (I/M) 25 mg 17-OHPC (0.1 ml Proluton® dissolved in 0.9 ml oil-based vitamin AD3E injectable solution) on day (D) 0 and PGF2 α (125 mg) on D10. Rested Saanen bucks (n=5) were introduced on D10 to does and kept for 7 days for mating. Blood samples were obtained from does for serology to measure P4 concentrations on D0, D10, D13 and D31. Serum P4 was measured using an enzyme immunoassay. There was no significant difference in serum P4 concentrations (mean \pm SEM) of samples collected on D0 (0.420 ± 0.178 ng/ml) and D10 (0.477 ± 0.126 ng/ml), but markedly decreased ($P < 0.05$) to 0.197 ± 0.026 ng/ml on D13. Then, a sharp increase ($P < 0.05$) was observed in serum P4 on D31 (1.165 ± 0.098 ng/ml). All does were confirmed to be pregnant through ultrasound scanning on D60. A total of 41 live kids were born. A doe with twin foetuses had died at the full-term pregnancy due to an intestinal torsion. Altogether 12 twin and 19 single births were obtained recording a 100% pregnancy rate. Based on farm records, live twin pregnancies were markedly higher (n = 14; 11 out of 14 were from the experiment) during the period, compared to the same month of the previous year (n = 1). In conclusion, the tested low-cost progestin-based synchronisation protocol can be utilised to maximise the breeding efficiency of female goats with proper nutritional management.

Keywords: 17- α -hydroxyprogesterone caproate, Goat, PGF2 α , Progestin, Synchronisation

Use of Vestibular Cytology as an Indicator for Estrous Detection and Artificial Insemination in Crossbred Goats

M.B.D. Lakmalie¹, G.D.R.K. Perera², R.M.C. Deshapriya³, D.M.S. Munasinghe⁴ and
R.M.S.B.K. Ranasinghe^{4*}

¹*Veterinary Research Institute, Gannoruwa, Peradeniya*

²*Department of Farm Animal Production and Health, Faculty of Veterinary Medicine and Animal Science*

³*Department of Animal Science, Faculty of Agriculture,*

⁴*Department of Basic Veterinary Sciences, Faculty of Veterinary Medicine and Animal Science, University of Peradeniya, Peradeniya, Sri Lanka*

**Corresponding Author: bimalkarana@pdn.ac.lk*

The improvement of the reproductive efficiency of crossbred goats will contribute to the increase of milk and meat production. The success rate of artificial insemination in goats in the country is low due to various reasons such as poor detection of estrus and increased timing of AI. Vaginal cytology has been reported to be a sensitive indicator to determine the stages of the estrous cycle and may be useful to identify the goats in estrous, thereby increasing the probability of the detection of estrous and improving conception rates. Therefore, the objective of this study was to study the changes of vestibular cytology during the estrous cycle. Ten crossbred (Sanan x Jamnapari), non-pregnant goats in 1st to 4th parity were selected from Udaperadeniya Veterinary Teaching Farm and estrous was synchronised using progesterone implants (20 mg) for 20 days and injections of PMSG (400IU) on the day of implant removal. The presences of follicles was confirmed by trans rectal ultrasonography (7.5MHz) which was performed from day 1 (day of removal of progesterone) to day 5. Herd was visited in the morning and vestibular impression smears were prepared daily from day 1 to day 30. The smears were dried, stained with Giemsa stain, observed under a light microscope and the percentage of each cell type (parabasal, superficial, keratinised and intermediate) was determined. The mean percentage of each cell type on each day was compared using repeated-measures ANOVA in SPSS. The diameter of the developing follicles increased from day 1, the highest diameter (0.8 ± 0.2 cm) was recorded on day 3 and these follicles were absent on day 4. The percentage of superficial cells showed a significant increase on day 2, 3 and 4 reaching to the highest on day 5 (73.5 ± 3.95 , 78.7 ± 3.95 , 81.4 ± 3.7 and $82.8 \pm 4.5\%$, respectively). The percentage of keratinised cells was low from day 1 to 5 and increased thereafter and the highest was recorded on day 8. It can be concluded that vestibular cytology is dominated by superficial cells representing more than 70% during the oestrous of the studied crossbred goats.

Keywords: Goat Artificial Insemination, Goat Vestibular cytology, Goat estrous detection

Effect of Climate and Management Conditions on Production Parameters of Selected Commercial Layer Strains

N.M.I.D. Karunadasa^{1*} and C.M.B. Dematawewa²

¹*Sri Lanka School of Animal Husbandry, Department of Animal Production and Health, Kundasale*

²*Postgraduate Institute of Agriculture, University of Peradeniya, Peradeniya*

*Corresponding Author: dhanoji11@gmail.com

The performance of imported commercial layer strains may vary according to the climatic and management conditions in different regions of Sri Lanka. This study was conducted to determine the effects of strain and age of the hens on laying performance and mortality of commercial layers in an intensively managed Government farm in Badulla district. Average temperature and rainfall of the area were 21⁰C and 1400 mm, respectively. The layers were reared in five poultry houses in close proximity under the same feeding and management conditions. Three popular commercial strains namely *Shaver Brown*, *Bovans Brown* and *Lohmann Brown* were reared randomly in separate cages (7 batches/strain) in those houses during the period from 2014 to 2019. The birds were given adequate spacing, fed with the standard layer rations, and vaccinated for IBD and New Castle disease. Ages of layers were categorized into 6 groups in 150-day intervals as <150, 151-300, 301-450, 451-600, 601-750, and >751 days, respectively. Age at sexual maturity was measured when a batch records 5% laying. Hen day production percentage (HDP) was calculated (n=7426 records) based on the flock size each day. Total mortality during the 150-day interval was used to calculate mortality percentage of the age group. ANOVA procedure was carried out, treating strain, age group, poultry house and their interactions as fixed effects and Duncan's New Multiple Range test was used for mean comparison. The three strains were significantly different from one another for HDP (P<0.05). Lohmann Brown recorded the highest HDP (65.4%) while *Shaver Brown* and *Bovans Brown* showed relatively lower HDP (58.6%, and 50.7%, respectively) where the typical strain standards for HDP were above 88%. Overall mean age at sexual maturity was 147 days with no significant differences among strains (P>0.05). Birds in the age groups 2 and 3 showed the highest HDP (64.5% and 63.1%, respectively (P<0.05). Overall mortality% was high (16.6%) though strains or age groups showed no significant differences (P>0.05). This study shows the importance of selecting the proper layer strain, and the need for much better management conditions to achieve a higher egg production in colder climates in Hill Country.

Keywords: Poultry Breeds, Laying Percentage, Layer Strain, Poultry Housing, Upcountry.

Effect of Egg size and Flock Age on Post-hatch Weight of Day Old Chicks of Village Chicken (*Gallus gallus*)

U.G.V.S.S. Kumara¹, C.M. Keerthirathne², M.M.D.D. Bandara¹, A.B. Amunugama¹, M.B.D. Lakmalie¹ and L.G.S. Lokugalappatti^{3*}

¹*Veterinary Research Institute, Gannoruwa, Peradeniya*

²*Animal Breeding Division, Department of Animal Production and Health*

³*Faculty of Veterinary Medicine and Animal Science, University of Peradeniya*

*Corresponding Author: vindyassk@gmail.com

The indigenous chicken rearing system is much popularised among backyard poultry farmers in Sri Lanka. Even though village chickens are reared mainly for egg-laying purposes, surplus cockerels and old birds are used to provide meat in rural areas. Better weight of Day Old Chicks (DOCs) is an important factor to gain more economic value from meat selling. Even though research has been performed to find out the relationship between egg size and flock age on post-hatch chick weight of commercial poultry, this information are limited on village chicken in Sri Lanka. Therefore, an investigation was carried out to study the effect of egg size (small, medium, and large) and flock age on post-hatch chick weight (20, 32 and 45 weeks) of village chickens at Central Poultry Research Station (CPRS), Karandagolla. A total of 900 eggs collected from 1st day of each week for 6 week period from each batch were transferred to the hatcher (80% RH /99°F). The ideal hatchability (91%-95%) and moisture loss (11%-15%) were observed on 18 days of incubation of all three batches. The weight of resulted DOCs was categorised according to the egg size for all three batches. The variance analysis showed a significant difference ($P \leq 0.05$) among the means of egg weight and weight of DOCs in all three batches with ideal moisture losses and hatchability. This showed that the egg weight increases with the breeder age of village chickens. Smaller chicks (32.368 ± 0.193 g) were produced by small eggs (46.648 ± 0.163 g) by the young-aged flock and heavier chicks (42.658 ± 0.718 g) were produced by large eggs (62.328 ± 0.677 g) from the old flock. This result was shown a strong positive correlation ($r^2 = 0.840$) between egg weight and chick weight. Therefore, this study concluded that the chick weight was improved with incubation of larger eggs of village chickens with the ideal level of moisture losses and hatchability percentage for more economic benefit.

Keywords: Village Chicken, Egg weight, Day Old Chick's weight, Central Poultry Research Station

Artificial Insemination of Sheep in Sri Lanka: A Successful Preliminary Study

S. Premaratne^{1*}, S. Kalubowila¹, C. Kannangara², S. Disnaka¹, G.D.R.K. Perera³ and M.P.S. Magamage^{1,4}

¹National Livestock Development Board, No.40, Nawala Road, Narahenpita, Colombo 5

²State Ministry of Livestock, Farm Promotion and Dairy and Egg Related Industries, No. 80/5, Ground Floor, "Govijana Mandiraya", Rajamalwatta Lane, Battaramulla

³Department of Farm Animal Production and Health, Faculty of Veterinary Medicine and Animal Science, University of Peradeniya

⁴Department of Livestock Production, Faculty of Agricultural Sciences, Sabaragamuwa University of Sri Lanka, Belihuloya

*Corresponding Author: sameera_premaratne@yahoo.com

'Madras Red', 'Bannur' and 'Jaffna Local' are the dominant breeds of sheep in Sri Lanka and are reared for the purposes of meat, manure blood for agar preparation in diagnostic microbiology, and breeding materials. Inbreeding and the absence of a programme for genetic upgrading are the key reasons for the slow growth rate of the present sheep population. The objective of the current study was to carry out artificial insemination (AI) programme for the existing sheep population in farms of the National Livestock Development Board (NLDB) with the aim of genetic upgrading. Under this programme, healthy 'Bannur' and 'Madras Red' cross bred ewes (n=114, 1st-3rd parities) were injected with 3 ml of vitamin E and Se (BIO-SELVIT E[®]) intramuscularly, at the day (D) 01 of the programme to the animals reared under intensive management at Horrakelley NLDB farm. Oestrous Synchronization of those ewes was achieved using slow progesterone (300mg) releasing intra-vaginal devices (EAZI-BREED CIDR[®]) at D14 of the program. Due to the dropping of the devices in several ewes, the remaining CIDR (n=98) were removed at D28 of the program. Intra-cervical single AI (n=98) was performed at 54-56 hours from the removal of CIDR[®], with frozen-thawed 'Australian White' semen imported from 'Total Livestock Genetics', VIC, Australia. Ewes were scanned (7.5MHz, Bond-way, China) per-rectally at 45-60 days after insemination for the confirmation of pregnancy. The AI success rate was 21.4%, while total of 19 live births consisting of 11 males (57.9%), 8 females (42.1%) and 2 abortions were recorded. One lamb died at the age of one month due to emphysematous abomasitis. The average gestation length and birth weight of lambs were 156.41±10.96 days and 2.61±0.43 Kg, respectively. Out of this study, 13 lambs are presently in breedable age, and 8 rams will be used to upgrade the existing flock. This is the first record of conducting AI in sheep in Sri Lanka. The study revealed the feasibility of conducting AI in sheep under the local conditions and the potential of introducing new genetic materials to the local sheep population to develop best fitted, economically viable sheep breeds for the country.

Keywords: Sheep, Artificial Insemination, Oestrus Synchronization

New Dimensions of Swine Breeding through Artificial Insemination in Sri Lanka

S. Premaratne^{1*}, S. Disnaka¹, G.D.R.K. Perera² and M.P.S. Magamage^{1,3}

¹National Livestock Development Board, No.40, Nawala Road, Narahenpita, Colombo 5

²Department of Farm Animal Production and Health, Faculty of Veterinary Medicine and Animal Science, University of Peradeniya

³Department Livestock Production, Faculty of Agricultural Sciences, Sabaragamuwa University of Sri Lanka, Belihuloya

*Corresponding Author: sameera_premaratne@yahoo.com

Artificial insemination (AI) of swine is not a common practice in Sri Lanka. Compared with natural mating, AI is a useful tool to introduce superior genes into breeding herds, with minimal risk of diseases despite the procedural cumbersomeness such as limitations of quality semen, skilled technicians, and heat detection issues. The Swine breeding project was established at Horakelley Farm of National Livestock Development Board (NLDB) and enrolled healthy 120 purebred Land Race (LR; n=50), Large White (LW; n=50 and Duroc (DU; n=20) sows to the operation and was subjected to artificial insemination during the period of 2018 to 2020. AIs were conducted using deep-frozen semen imported from Swine Genetics International, USA. The heat was detected by visual changes of the animal and by performing back pressure tests. A single AI was carried out between 33-36 hours and 29-32 hours for sows and gilts, respectively. The semen extender solution (Modena®) had to be prepared by mixing one pack of Modena® extender (48g) in one liter of autoclaved distilled water (35 °C) and store under freezing conditions (-20 °C). Subsequently, 80 ml of the prepared extender solution was thawed up to 20 °C. Then mixed with semen (5ml) that was thawed at 50 °C for 45 seconds in a water bath. The semen solution was maintained at 20 °C in RP mini cool box until insemination. Intra cervical insemination was performed using a Genepro® soft-touch catheter. Bred animals were examined for non-returning into heat at 18-24 days after the insemination for tentative confirmation of pregnancy. AIs (n=116) were performed during the period. Subsequent farrowing (n=36) was recorded (LW; n=17, LR; n=15, DU; n= 4) and the AI success rate was measured at 31.03% while the average litter size was 7.8 ±3.2 (LW; n=8.5, LR; n= 7.6, DU; n=6.2). Among the offspring, the male to female ratio was 54: 46 (LW; 61:39, LR; 46:54, DU; 44:56). This result indicates that AI on naturally detected heat can be successfully applied for swine breeding programs, mainly among the breeding stocks in the country, with minimum technical intervention.

Keywords: Swine, Artificial Insemination, Deep Frozen Semen, Semen Extender

A case report of Parasitic Co-infection in Goldfish (*Carassius auratus*)

H.M.M. Madushani, D.M.W.C.J. Dissanayake and D.P.N. De Silva*

Department of Animal Science, Faculty of Animal Science and Export Agriculture, Uva Wellassa University, Badulla, Sri Lanka

*Correspondence: prasadi@uwu.ac.lk

Parasitism is the most common disease problem in aquarium fish and may lead to mortality if unattended. Co-infections lead to severe clinical conditions and often complicate the treatment plan. *Hexamita* (*Spironucleus*) is an internal parasite found within the intestinal tract of freshwater fish, which complete part of their life cycle outside the host. It causes “hole in the head” in freshwater fish. Skin flukes (*Gyrodactylus* sp.) are abundant metazoan ecto-parasites present in fish. This case study reports a treatment protocol used for co-infection with *Hexamita* and skin fluke in goldfish reared in an aquarium glass tank. Three adult goldfish approximately six years of age, average length, and weight of 16.7 cm and 55.17 g were found with deep lesions on and around sensory pits at the dorsal side of their heads. Fin rot and hemorrhagic patches near the eyes, operculum, the base of the pectoral and caudal fins was also observed. White faecal cast hanging from the anus was found in all three fish. Infected goldfish were separated into a treatment tank (50 L capacity). Wet mount preparations from skin scrapings revealed mild infestation with skin flukes and scrapings from the lesion on the head had heavy infestation with flagellated protozoa *Hexamita* sp. under 400x light microscopy. Metronidazole, the drug of choice for spironucleosis (hexamitiasis), was accompanied by a salt bath and vitamin C to treat skin flukes. The initial bath treatment for the infected fish was 5 mg/L of metronidazole (Flagyl), 0.4g/L of salt, and 2.5mg/L of vitamin C into 50 L glass tank for three days. Metronidazole treatment (5 mg/L) was continued once every three days, followed by 1/3 of water change to maintain optimum water quality. One fish with a severe lesion on the head and haemorrhages on the fins died two days after treatment. Post-mortem findings of the intestinal tissue squash revealed the presence of *Hexamita* sp. The other two fish became negative for skin flukes and *Hexamita* parasites on wet mounts after three weeks, but the faecal examination revealed the presence of *Hexamita* sp. Hence metronidazole (25 mg/kg) was supplied orally and both fish recovered from hexamitiasis one month after the initial examination.

Keywords: *Hexamita*, *Spironucleus*, Goldfish, Hole in the head, Hexamitiasis

Growth Performance and Survival of Indian Major Carp *Catla catla* Post larvae Fed with Different Density of Freshwater Zooplankton *Daphnia magna*

P.A. Sanduni Madhushani¹, M.N.M.Fouzi^{2*} and P.M.Withanage³

¹*Department of Biosystems Technology, South Eastern University of Sri Lanka*

²*Department of Farm Animal Production and Health, Faculty of Veterinary Medicine and Animal Science, University of Peradeniya, Peradeniya*

³*National Aquaculture Development Authority, Udawalawe*

*Corresponding Author: mnmf@pdn.ac.lk

Catla catla (Catla) is the fastest-growing fish species in the Indian major carp group and is rich in proteins. The growth performance and survival of Catla are low in Sri Lankan conditions. *Daphnia magna* (Daphnia) is a type of micro crustacean containing 20% -27% lipid, 45- 85% protein, and abundant enzymes, a natural feed. Therefore an experiment was conducted to examine the effect of feeding live Daphnia, with concentrate feed on the survival and performances of Catla post larvae (PL). The emblematic floating cages (60cm×30cm×30cm) were made to grow Daphnia in the fish tanks with the 2mm cell net size to facilitate the release of newly born Daphnia to fish larvae. Three treatments, each with three replicates set up by using the concrete tank, each stocked with 5000 PL at the stocking rate of 300 PL per m³. Each daphnia cage was stocked with 100,000 Daphnia in the first week and 50,000 in the second week. Fish larvae in treatment 1 were fed only by commercial carp feed, while tanks of treatment 2 were fed with one cage of Daphnia and commercial feed and treatment 3 were fed with two cages of Daphnia and commercial feed. The same amount (1% of the PL's body weight) of commercial feed was given to all experimental tanks. The mean weight, mean length, and water quality parameters were measured just before the trial and every three days afterwards, up to 21 days. The weight gain and specific growth rate (SGR) were calculated. The highest survival rate (78.70%) and specific growth rate were found in treatment 3. The PL fed with feed treatment 3 showed significantly ($p < 0.05$) highest mean length (35.0 ± 1.7 mm) and mean weight (4.43 ± 0.12 mg). The average daily growth (1.35 ± 0.1) and specific growth rate (7.3 ± 0.1) of treatment 3 were significantly higher than other treatments. The high content of protein in Daphnia could have increased the growth of Catla fry. The present study concluded that Daphnia supplementation (About 300,000) per 5000 PL together with concentrate feed increases survival when compared to feeding with concentrate feed alone.

Keywords: *Daphnia magna*, *Catla catla* (Catla), Live feed, Growth and Survival

Systemic Aspergillosis in a Captive Newly Hatched Emu Chick (*Dromaius novaehollandiae*)

P. Ediriwarne¹, I. Rathnayake², A. Palkumbura², T. Gunawardena², C. Rajapaksha³, R. Jinadasa² and K. Wijesundera^{2*}

¹Ridiyagama Safari Park, Department of National Zoological Gardens, Sri Lanka

²Department of Veterinary Pathobiology, Faculty of Veterinary Medicine & Animal Science, University of Peradeniya, Peradeniya, Sri Lanka

³Department of National Zoological Gardens, Dehiwala, Sri Lanka

*Corresponding Author: kavindra@vet.pdn.ac.lk

Aspergillosis is the most common opportunistic fungal infection of the respiratory tract in birds. Acute cases have been reported following the inhalation of a high dose of spores, such as that which occurs in confined moist environments. *Aspergillus fumigatus* accounts for around 95% of cases and *A. flavus* is the second most common organism associated with avian infections. Infections in other sites, including visceral organs, liver, eye, and brain, have been reported. Warm and humid environments tend to predispose the birds to this disease. Treatment is usually difficult and lengthy in birds. A one-month-old Emu (*Dromaius novaehollandiae*) chick hatched at the Ridiyagama Safari Park died after showing signs of respiratory difficulty and anorexia for two weeks. On post-mortem examination, conjunctival and oral mucosae appeared pale. In addition, multifocal grey to yellow, raised, irregular nodules (2 mm in diameter) were observed in the lungs, air sacs and the peritoneum. Furthermore, the lungs and air sacs appeared congested and oedematous. Tissue samples were fixed in 10% neutral buffered formalin and underwent routine tissue processing. A Lung sample was cultured in blood agar and Sabouraud dextrose agar (SDA), and incubated aerobically at 25 °C. A cottony mycelium appeared first on SDA and changed colour to yellow-green later. Wet mount stained with lactophenol cotton blue stain showed characteristic ‘fruiting head’ appearance of the *Aspergillus spp.* Round vesicles with sporulation over the entire surface were observed, suggestive of *A. flavus* infection. The sample was negative for aerobic bacterial culture. Formalin-fixed, wax-embedded tissues were sectioned at 2 mm thickness and stained with hematoxylin and eosin (HE) and periodic-acid Schiff (PAS). Variable sized granulomas were observed in HE stained lung parenchyma. Developing fungal hyphae with acute angles in branching was also seen in the PAS-stained sections. The findings suggest that aspergillosis should be considered a differential diagnosis in respiratory diseases among young captive wild birds in Sri Lanka.

Keywords: Emu, Aspergillosis, Histopathology, Microbiology

High Occurrence of Multi-drug Resistance among Gram-Negative Bacterial Pathogens in Freshwater Ornamental Fish

D.M.P.M. Dhanapala¹, R.S. Kalupahana¹, A.W. Kalupahana¹, D.P.H. Wijesekara¹, K.S.A. Kottawatta¹, N.K. Jayasekera¹, A. Silva-Fletcher² and S.S.S.de S. Jagoda^{1*}

¹*Faculty of Veterinary Medicine and Animal Science, University of Peradeniya, Peradeniya, 20400, Sri Lanka*

²*Royal Veterinary College, University of London, NW10TU, United Kingdom*

*Corresponding Author: samanthika@vet.pdn.ac.lk

Ornamental fish constitute an emerging segment in the pet industry. The bacterial disease is one of the commonly encountered health issues of tropical freshwater ornamental fish. Most bacterial infections are caused by Gram-negative bacteria inhabiting the aquatic environment. In the ornamental fish industry, antimicrobials are widely used both therapeutically and prophylactically without proper veterinary intervention. Long term misuse and abuse of antimicrobials have resulted in the development of drug resistance in aquatic bacteria. The present study aimed to characterize Gram-negative bacteria isolated from diseased freshwater ornamental fish and to evaluate their antimicrobial susceptibility. Ornamental fish with septicaemic signs collected from breeding farms or aquaria or submitted to Centre for Aquatic Animal Disease Diagnosis and Research (CAADDR) for disease investigation were used for the study. Kidney samples and/or swabs from ulcers were cultured on tryptic soy agar. After preliminary biochemical identification, Gram-negative rods (oxidase-positive, fermentative in oxidation fermentation test) were subjected to polymerase chain reaction amplification of *gyrB* gene (1100 bp). Species identification was done by the partial sequence analysis of *gyrB* gene. Isolates were subjected to antimicrobial susceptibility testing by disk diffusion method according to CLSI guidelines. Forty-two Gram-negative, oxidase-positive bacterial isolates were recovered from 29 fish that belonged to eight different species. According to *gyrB* sequence analysis, *Aeromonas* spp. was the most dominant (35/42, 83.3%) that included *A. veronii* (38.1%), *A. hydrophila* (28.6%), *A. jandaei* (11.9%) and *A. dhakensis* (4.8%). The rest comprised of *Citrobacter freundii* (4.8%), *Morganella morganii* (2.4%), *Enterobacter roggenkampii* (2.4%), *Shewanella decolorationis* (2.4%), *Phytobacter diazotrophicus* (2.4%) and *Plesiomonas shigelloides* (2.4%). The highest resistance was observed against amoxicillin (92.9%) followed by enrofloxacin (76.2%), nalidixic acid (61.9%), tetracycline (45.2%), erythromycin (35.7%), sulpha-trimethoprim (28.6%), gentamicin (23.8%), imipenem (21.4%), doxycycline (14.3%), nitrofurantoin (11.9%), chloramphenicol (9.5%), rifampicin (4.8%) and ceftazidime (2.4%). The majority of isolates were multi-drug resistant (71.4%, $n=30$), while 36.7% (11/30) of those were resistant to ≥ 5 antibiotic classes. Of all, 78.6% ($n=33$) showed multiple antibiotic resistance (MAR) index >0.2 . The alarmingly high resistance levels in fish bacterial pathogens observed in this study highlight the requirement of veterinary interventions in the health management of ornamental fish to safeguard this thriving industry.

Keywords: Freshwater Ornamental Fish, Gram-negative Bacteria, Antibiotic Resistance, Multi-drug Resistance, Multiple Antibiotic Resistance

Acknowledgement: Financial support rendered through UKRI Research England under the Bloomsbury SET Knowledge Exchange programme (grant no CCF-17-7779), Royal Veterinary College, University of London, UK

Parasitic Dinoflagellate, *Hematodinium* spp. as a Cause of Heavy Mortality in Cultured Mud Crab (*Scylla serrata*) in Sri Lanka

R.M.I.M. Rathnayake¹, R. M. N. P. K. Ranathunga², A.W. Kalupahana¹, G.S.P.de S. Gunawardena¹ and S.S. S de S. Jagoda^{1*}

¹Department of Veterinary Pathobiology, Faculty of Veterinary Medicine and Animal Science, University of Peradeniya, Peradeniya 20400, Sri Lanka

²National Aquaculture Development Authority of Sri Lanka, Ministry of Fisheries and Aquatic Resources, Maligawatte Rd, Colombo 01000, Sri Lanka

*Corresponding Author: samanthika@vet.pdn.ac.lk

The mud crab (*Scylla serrata*) is a promising aquaculture species. The supply of mud crabs in Sri Lanka largely depended on fattening wild-caught juvenile crabs in earthen ponds. However, the commercial culture of mud crabs has become popular in recent years. A disease outbreak characterized by high mortality (60-100%) was reported in mud crabs cultured in earthen, monoculture, brackish water ponds in the coastal areas of the North-Western Province from November-December 2020. After stocking hatchery bred crablets in mud ponds at stocking densities of 1000-3000/acre, significant mortality was observed in sub-adult to adult crabs of 2-7 months in many farms. Crabs originated from wild-caught crablets were also affected. To investigate the aetiology of this outbreak, eight live mud crabs were sampled from three affected farms in the Puttalam district. Crabs showed lethargic and moribund behaviour, dull carapaces with varying degrees of epidermal hyperpigmentation and absence of one or several pereopods. Crabs were anaesthetized by chilling at 4 °C on ice, subjected to external examination and necropsy. The affected crabs had opaque to white colour hemolymph with delayed clotting time. Direct microscopic examination of smears of hemolymph (stained with hematoxylin and eosin after fixation with Bouin's solution) showed a high number of *Hematodinium*-like parasites in various stages of development. Histopathology of internal organs, including hepatopancreas and gills, showed marked depletion of hemocytes and presence of numerous protozoans with the characteristics of *Hematodinium* spp. in the haemal vessels and sinuses. The presence of the parasite was further confirmed by conventional polymerase chain reaction amplification of *Hematodinium* 18S rRNA gene using *Hematodinium*-specific primers 5' -cct ggc tcg ata gag ttg and 5' -ggc tgc cgt ccg aat tat tca c from hemolymph DNA. Parasitic dinoflagellates of the genus *Hematodinium* are significant pathogens affecting the global decapod crustacean fishery. Our findings confirm that *Hematodinium* spp. is associated with this outbreak. This is the first documented disease outbreak caused by *Hematodinium* spp. in mud crabs in Sri Lanka. The results suggest that *Hematodinium* spp. represents a significant threat to the future sustainability of emerging mud crab culture in the country.

Keywords: *Hematodinium*, Mud crab, *Scylla serrate*

Detection of Infectious Spleen and Kidney Necrosis Virus (ISKNV) Infection in Freshwater Ornamental Fish from Two Provinces of Sri Lanka

D.M.P.M. Dhanapala, R.M.I.M. Rathnayake, D.M.S.G. Dissanayaka, R.R.M.K.K. Wijesundera, A.W. Kalupahana and S.S.S de S. Jagoda*

Department of Veterinary Pathobiology, Faculty of Veterinary Medicine and Animal Science, University of Peradeniya, Peradeniya 20400, Sri Lanka

*Corresponding Author: samanthika@vet.pdn.ac.lk

Infectious spleen and kidney necrosis virus (ISKNV) of the genus *Megalocytivirus* of family *Iridoviridae* is an important pathogen of ornamental fish causing serious systemic disease associated with high mortality. Clinical outbreaks of ISKNV have reported to cause severe economic losses in ornamental fish among which cichlids, livebearers, angelfish and gourami are highly susceptible. There had been a report of ISKNV in sea bass cultured in Sri Lanka based only on histopathological identification. This study aimed to detect the presence of ISKNV in freshwater ornamental fish stocks that experienced heavy mortality in Sri Lanka. Ornamental fish samples (from stocks that experienced unexpected, heavy mortality) collected from breeding farms and aquaria or submitted to Centre for Aquatic Animal Disease Diagnosis and Research (CAADDR) for disease investigation were used in the study. At least 2-5 fish from each incidence were subjected to external examination and necropsy. DNA was extracted from the gills and pooled internal organs (kidney, liver, spleen) of all fish. The presence of *Megalocytivirus* was confirmed by PCR using a universal primer set for all megalocytiviruses [specific for three major genotypes; Red Sea-bream iridovirus (RSIV), infectious spleen and kidney necrosis virus (ISKNV) and turbot reddish body iridovirus (TRBIV)] and subsequent sequence analysis. Samples from selected stocks were fixed in 10% neutral buffered formalin and routinely processed for histopathology. Out of 25 samples examined, eight samples [Western province (n=2), Central Province (n=6)] gave positive results by PCR. These included 03 samples of swordtail (*Xiphophorus helleri*), 01 samples each of angelfish (*Pterophyllum scalare*), giant gourami (*Osphronemus goramy*), goldfish (*Carassius auratus*), zebrafish (*Danio rerio*) and fighter fish (*Betta splendens*). Affected fish showed non-specific clinical signs such as anorexia, lethargy, darkening, erratic swimming, and abdominal distension. Histopathology showed hypertrophic cells, lymphocytic infiltration and single-cell necrosis in the liver and kidney. A moderate number of hypertrophied cells were present adjacent to renal tubules. Molecular phylogenetic analysis confirmed that *Megalocytivirus* in the current study belongs to ISKNV with 100% nucleotide homology. Our results confirmed the presence of ISKNV in various species of ornamental fish in Sri Lanka. Active disease surveillance is warranted to understand the true burden of this emerging disease.

Keywords: Ornamental fish, *Megalocytivirus*, Infectious Spleen and Kidney Necrosis Virus

Acknowledgement: Financial support by University Research Grant URG/2016/66/V

Mortality, Rescue and Release Statistics of *Panthera pardus kotiya* in Central Hills of Sri Lanka during 2019 and 2020

M. A. Pinidiya^{1*}, V.P.M.K. Abewardhana¹, B.D.S. Jayawardhana¹, G.A.T. Prasad¹, C.G. Wijesinghe², R.R.M.K.K. Wijesundara³ and L.G.S. Lokugalappatti³

¹ Department of Wildlife Conservation, Sri Lanka

² Department of Animal Production and Health, Gatambe, Sri Lanka

³ Department of Veterinary Pathobiology, Faculty of Veterinary Medicine and Animal Science, University of Peradeniya, Peradeniya, Sri Lanka

⁴ Department of Basic Veterinary Sciences, Faculty of Veterinary Medicine and Animal Science, University of Peradeniya, Sri Lanka

*Corresponding Author: akalankapinidiya@gmail.com

Sri Lankan leopard (*Panthera pardus kotiya*) is the subspecies of leopard that is endemic to Sri Lanka. It is a strictly protected mammal in Sri Lanka and has been listed under the vulnerable category by the IUCN since 2020, owing to recent population decline. The existence of this top predator on the island is threatened by rapid habitat loss, habitat fragmentation and poaching for skins and canines, as well as trapping in snares intended for other wild species. This paper aims to analyse the post-mortem findings and cases of casualties of leopards in the Central Hills in Sri Lanka reported during 2019 and 2020. During the study period, a total of 24 leopard cases, including post-mortems and casualties, were attended by the veterinarians. Of the total 24 cases, six were reported in 2019, while the rest (18) were reported in 2020. Out of 24 cases, the sex of one case could not be determined due to either carcass already having decomposed, or only part of the carcass was recovered. There were 13 male and ten female animals among the cases in which sex could be determined, highlighting the higher casualties among the male leopards. Of the 24 cases, 13 were already dead and the other 11 were alive at the time of veterinary intervention. Among the 13 dead leopards, most (09) were due to complications caused by snare trapping, two were due to gunshot wounds, one was due to poisoning and one was due to suspected infection. The approximate estimated age of the already dead leopards ranged from one year to nine years and among them, there were six males and six females. All ten rescued leopards were trapped in snares set in close proximity to tea plantations. Three out of eleven rescued leopards (two female and one male) were succumbed to death due to complications while being treated. Other eight were treated and released without any complications, among which there were six males and two females. All released leopards were less than four years old, perhaps indicating a high chance of recovery.

Keywords: Sri Lankan Leopard, Rescue, Rehabilitation

Insights into Research on Infectious Diseases in Ornamental Fish and Cultured Food Fish in Sri Lanka: Trends and Gaps

D. Gunaratne and E. Pathirana*

Faculty of Fisheries & Ocean Sciences, Ocean University of Sri Lanka, Mahawela Road, Tangalle

*Corresponding Author: erandip@ocu.ac.lk

Aquaculture health management continues to be a challenge in the global aquaculture trade. An accurate estimate of the disease burden is instrumental in disease control. The objective of this study was to review research reporting infectious diseases in ornamental fish and cultured food fish in Sri Lanka. Research publications (n =24) addressing infectious diseases in Sri Lankan aquaculture and those studies reporting the presence of infectious agents in fish originating from Sri Lanka were analysed based on the following keys: frequency of study, commonly affected species of fish, screening/diagnostic approach, the efficacy of treatment protocols. Both parasitic diseases and bacterial diseases have been equally researched (41.67 %, 10/24 each). Viral diseases were less studied (20.83 %, 5/24) and even those present were surveillance studies reporting the presence/absence of a virus. A wide range of parasites including protozoans (*Tetrahymena* spp., *Trichodina* and *Chilodonella* to name a few), monogenean trematodes (*Dactylogyrus* spp. and *Gyrodactylus* spp.), digenean trematodes (*Centrocestus* spp.), parasitic crustaceans (*Argulus*, *Ergasilus* and *Lernaea*) and nematodes (*Capillaria* spp.), were present in ornamental fish. Only two studies reported parasites in food fish. *Aeromonas* spp., *Mycobacterium* spp. and *Vibrio* spp. were among the bacteria associated with diseased fish, and half of these studies employed molecular techniques for characterization of bacteria. *Aeromonas* spp. have been isolated from 25.0 % (6/24) of the studies. These *Aeromonas* isolates showed resistance to a range of antibiotics tested, including tetracyclines, penicillins, trimethoprim-sulfa and erythromycin but showed sensitivity to quinolones. A surveillance study in a fish breeder farm has concluded that Sri Lanka may be free from *Spring viraemia of carp virus* (SVCV). Another study indicated the suspected presence of SVCV, *Red sea bream iridovirus* and *Koi herpesvirus*. *Megalocytivirus* was present in fish (gourami) exported to Australia. In conclusion, the need for conclusive surveillance studies on commonly encountered viruses in ornamental fish was identified. Detection of *Megalocytivirus* and monogenean ectoparasites in our ornamental fish during international border quarantine highlights re-consideration of pre-export veterinary certification procedures. Identification of monogenean trematodes (*Trianchoratus* spp. and *Urocleidoides reticulatus*) in fish imported from Sri Lanka, which has not been reported in local studies, indicates the importance of comprehensive parasitic studies in ornamental fish.

Keywords: Infectious diseases, Ornamental fish, Food fish, Sri Lanka, Trends, Gaps

Occurrence of *Paradujardinia halicoris* in a Dead *Dugong dugon* in Kilinochchi, Sri Lanka

P.G.I.D. Amarasiri^{1*}, M.D.S. de Silva², B. Giridharan², R. Gowrithilagan³, A.M.H. Atapaththu¹
and N.C. Gamagedara¹

¹*Veterinary Research Institute, Gannoruwa, Peradeniya*

²*Department of Wildlife Conservation, Sri Lanka*

³*Veterinary Investigation Center, Kilinochchi*

Corresponding Author: idadamasiri@gmail.com

Dugong dugon, generally known as Dugong is the only marine mammal species of the family *Dugongidae*. They are distributed in the coastal waters of Indo and West- Pacific regions. In Sri Lanka, the Dugong species is critically endangered and, therefore, strictly protected under the Fauna and Flora protection ordinance. Many parasitic diseases such as Cryptosporidiosis, Toxoplasmosis and infection with numerous helminths are reported in dugongs. *Paradujardinia halicoris* is the only nematode present in the stomach of Dugong. It causes inflammation and ulceration of the gastric wall. Knowledge on the occurrence of the parasite in dugongs that inhabit the marine environment around Sri Lanka will be helpful in the protection and conservation of this endangered species. In the present case, few nematode parasites have been isolated from the stomach and proximal duodenum of a Dugong at necropsy performed at Kilinochchi, Sri Lanka. The collected samples were fixed in 70% alcohol and sent to the division of Parasitology of Veterinary Research Institute, Peradeniya for identification of species. In the laboratory, nematodes were examined by macroscopic and microscopic methods to identify key morphological characters. The parasites were white in colour. The length of the studied parasites (n=4) averaged 10.3 ± 0.9 cm. The microscopic characters were observed under a stereotactic microscope. The head region was well demarcated from the neck and three lips were clearly identified. The sub ventral lips were larger than the dorsal lip. An excretory notch was observed 2-3mm below the head. The esophagus was 1-1.5 cm in length. The length from lips to anus averaged 10.17 ± 0.9 cm. Nine papillae of variable size were observed around the anus. Male parasites were non bursate with a pair of short spicules. No gubernaculum was noted. No female parasites were present in the studied sample. Macroscopic and microscopic findings and anatomical site of isolation of studied parasites are in consistent with characters of *Paradujardinia halicoris* described in previous studies. However, molecular detection is essential in the confirmation of the parasitic species and this will be conducted in the near future. According to our knowledge, this is the first written report on the occurrence of *Paradujardinia halicoris* in Dugongs in Sri Lanka.

Keywords: *Paradujardinia halicoris*, *Dugong dugon*, Nematode present in the stomach

A Retrospective Analysis of Ornamental Fish Submissions to a University-Based Fish Disease Diagnostic Laboratory

R.M.I.M. Rathnayake, D.M.P.M. Dhanapala, K.L.N. Ananda,
A.W. Kalupahana and S.S.S de S. Jagoda*

*Department of Veterinary Pathobiology, Faculty of Veterinary Medicine and Animal Science,
University of Peradeniya, Peradeniya 20400, Sri Lanka*

*Corresponding Author: samanthika@vet.pdn.ac.lk

The clinical and diagnostic findings of 110 ornamental fish samples submitted to the Center for Aquatic Animal Disease Diagnosis and Research (from July 2017-July 2021) were summarized by retrospective analysis of laboratory records. Hobbyists submitted 75% (83/110) of the cases followed by farms (13%, 14/110) and aquaria (12%, 13/110). Submitted fish belonged to 12 different species, among which koi carp (*Cyprinus carpio koi*) (23%), giant gourami (*Osphronemus goramy*) (14%), goldfish (*Carassius auratus*) (13%), guppy (*Poecilia reticulata*) (8%), oscar (*Astronotus ocellatus*) (7%) and arowana (*Osteoglossum* spp., *Scleropages* spp.) (6%) were the most frequent. Twenty four percent (26/110) of the cases had been submitted to investigate sudden and/or heavy mortalities. Reduced appetite (14%), dropsy (13%), abnormal swimming (10%), lethargy (9%), ulceration (7%), haemorrhages on skin (6%) and fin rot (5%) were the commonly observed clinical signs. Based on the history, external examination, necropsy findings (where appropriate) and the results of other diagnostic techniques, cases were grouped as infectious (92%, 101/110), tumour (6%, 7/110) and environmental (2%, 2/110). Among infectious cases, the majority (89%, 89/101) had single aetiology, which included either external parasites (48%, 48/101), systemic bacteria (32%, 32/101), external bacteria (2%, 2/101) or viruses (7%, 7/101). Cases with multi factorial aetiology (11%) had combinations of parasites and systemic bacteria (5%), parasites and viruses (2%), parasites and fungi (1%), systemic bacteria and viruses (3%) or external bacteria and fungi (2%). Among the parasitic infections/infestations reported (50%, 55/ 110), monogeneans (47%), *Trichodina* (20%), *Learnea* (9%), *Oodinium* (9%), *Ichthyophthirius* (7%), Metacercariae (7%), *Ichthyobodo* (5%), *Epistylis* (5%) and *Chilodonella* (4%) were the most frequently encountered, while some fish had multiple species of external parasites. Systemic bacterial infections (36%, 40/110) were associated mainly with Gram-negative bacteria (65%), followed by mycobacteria (33%) and Gram-positive bacteria (18%). Viral diseases (11%, 11/110) confirmed by Polymerase Chain Reaction included carp edema virus (42%), red sea bream iridovirus (33%) and *Megalocytivirus* (25%). The results show that there is a frequent occurrence of external parasites and bacteria associated with diseased freshwater ornamental fish. With the expansion of ornamental fish industry, there will be an increasing demand for quality diagnostic support. Therefore, a concentrated effort in improving diagnostic support will be immensely beneficial to this industry.

Keywords: Ornamental fish, Diseases, Diagnosis, Laboratory

Evaluation of the Nutritional Composition of Suckermouth Armoured Catfish (*Pterygoplichthys disjunctivus*) Collected from Reservoirs in Sri Lanka

W.M.L.A. Wanasinghe^{1,2}, M.N.M. Fouzi^{1*}, L.G.S. Lokugalappatti², H.B.S. Ariyaratne² and M.W.C.D. Palliyeguru³

¹Department of Farm Animal Production & Health, Faculty of Veterinary Medicine & Animal Science, University of Peradeniya, Peradeniya 20400, Sri Lanka

²Department of Basic Veterinary Sciences, Faculty of Veterinary Medicine & Animal Science, University of Peradeniya, Peradeniya 20400, Sri Lanka

³Animal Nutrition Division, Veterinary Research Institute, Peradeniya 20400, Sri Lanka

*Corresponding Author: mmmf@vet.pdn.ac.lk

The introduction of several sucker mouth armoured catfish species, including *Pterygoplichthys disjunctivus* (Family Loricariidae) into Sri Lankan water bodies, has posed a significant threat to native fish biodiversity and the livelihood of the traditional inland fisheries in Sri Lanka. A better understanding of the nutritive values of the *P. disjunctivus* species is a timely requirement to promote this fish as a raw material for animal feed. Therefore, the present study was aimed at determining the nutritional composition, including ash, protein, fat, crude fibre, mineral content, and fatty acid profile of *P. disjunctivus* in freshwater bodies of Sri Lanka. Seventy adults (total length ≥ 30 cm) *P. disjunctivus* were collected from Polgolla (n=30), Victoria (n=10), Udawalawe (n=10), Kalawewa (n=10) and Trincomalee-Janaranjana wewa (n=10) reservoirs in Sri Lanka. Proximate analysis was performed by categorizing under three weight groups of fish in the Polgolla reservoir (n=30) (200-400 g, 401-601 g and 602-802 g). The fatty acid profile of the fish was determined using the AOAC 996.06 method and saturated fat, monounsaturated fat, polyunsaturated fat, and others were tested. The mineral content of digested samples was determined by atomic absorption spectrophotometry. The data were analysed by the one-way ANOVA test using SPSS software (Ver. 26.0) and a P value less than 0.05 ($P \leq 0.05$) was considered as significantly different. The ash, crude protein, fat, and fibre contents of the weight groups of *P. disjunctivus* were 22.57 ± 5.28 %, 60.94 ± 5.98 %, 13.94 ± 5.60 % and 4.09 ± 1.20 % (mean \pm SD) respectively on a dry matter basis. Furthermore, the weight groups of the fish had significant relationships ($P \leq 0.05$) with nutrient content. The high mineral contents (mean \pm SD) were reported as Na 3.82 ± 0.29 g.kg⁻¹ in Udawalawa, Ca 8.95 ± 0.83 g.kg⁻¹ and P 13.72 ± 1.79 g.kg⁻¹ in Victoria, Mg 1.3 ± 0.58 g.kg⁻¹, K 6.00 ± 0.09 g.kg⁻¹, Cu 0.028 ± 0.02 g.kg⁻¹, Zn 13.44 ± 2.51 g.kg⁻¹ and Mn 13.17 ± 7.22 g.kg⁻¹ in Polgolla reservoir, whereas Co was not detected in any reservoir. The high content of saturated, monounsaturated, and polyunsaturated fatty acids was found as Palmitic Acid (C16:0) (33.4%), Oleic Acid (C18:1) (34.6%) and Linoleic Acid (C18:2) 6.7%, respectively, in the Polgolla reservoir. Furthermore, omega 3 fatty acids such as eicosapentanoic acid (EPA) and docosahexaenoic acid (DHA) were found to be as low as 0.3% and 1.0%, respectively. This study shows that the investigated fish species are good sources of many major nutrients and essential elements. Therefore, *P. disjunctivus* can be used as a raw material for protein and minerals in animal feed.

Keywords: *Pterygoplichthys disjunctivus*, Nutritional Composition, Invasive fish, Sri Lanka

Acknowledgements: The financial support of Peradeniya University Research Grant No. URG/2018/50/V, URG/2018/53/V and Fellowship AC/URF/2018/02 are acknowledged.

Evaluation of Export Performance of Ornamental Fish Industry in Sri Lanka

U.S Gunarathna^{1*}, C.S Gangani² and L.M. Abeywickrama²

¹*Department of Animal Production and Health*

²*Department of Agricultural Economics, Faculty of Agriculture, University of Ruhuna, Sri Lanka*

**Corresponding Author: sadishagunarathna@yahoo.com*

The ornamental fish industry shows a very high potential to make significant foreign exchange earnings for Sri Lanka. However, the potential of export-oriented ornamental fish industry has been hitherto underexplored. Therefore, the present study aims to evaluate the current export performance, and the export potential of export-oriented ornamental fish industry, while identifying the factors inhibiting exportation in order to suggest policy measures to develop the ornamental fish industry. This study was mainly based on secondary data obtained from 2010 to 2018. Questionnaire based interviews were also conducted in order to fill the gaps of secondary data. Revealed Comparative Advantage (RCA), Relative Import Advantage (RIA) and Relative Trade Advantage (RTA) were measured. A review of the secondary data revealed that Sri Lanka is among the top 10 ornamental fish exporters in the world and that freshwater fish, such as colourful Guppy, contributed about 70% of annual exports. The export earnings from the ornamental fish industry doubled from 2010 to 2018, which increased from 8.1 million the US \$ to 16.1 respectively. The top importer of Sri Lankan ornamental fish is the United States of America. In addition, United Kingdom, China, and Germany are also leading importers. Most interestingly, RCA has increased from 33 to 43.7, RIA increased from 0.87 to 8.5 and RTA has increased from 32.2 to 35.7 from 2010 to 2018 that show the high export potential of the industry. Interviews revealed that seventy (70%) of the interviewed exporters are small-scale exporters. Low government involvement, lack of an efficient supply chain, insufficient training on constructive and sustainable fishing methods are among the main factors inhibiting the sector to fulfill the export potential. The probable ways for moving forward were also discussed. Since there is a high export potential and competitive export potential in the ornamental fish industry, the study recommends formulating a strong policy framework to encourage breeders to use the resources inside the country to enhance the sector rather than import and re-export the ornamental fish. Moreover, the study recommends resolving the problems attached to the sector to reap maximum economic gain from the industry. The present study is of great significance for policymakers and ornamental fish exporters.

Keywords: Exportation, Ornamental Fish Industry, Problems and Constraints of Ornamental Fish in Sri Lanka



SRI LANKA VETERINARY ASSOCIATION

“Working for the advancement of the veterinary profession since 1940”

275/75, OPA Building,
Prof. Stanley Wijesundara Mawatha,
Colombo 07, Sri Lanka.

E-mail: info@slva.org Website: www.slva.org